

UDC: 616.5-006.81-089

**D.R. SANGINOV¹, Z.H. HUSEYNZODA², I.N. HUSEYNOV², F.Kh. RAIHONOV²,
I.K. NIYAZOV¹, A.Zh. ZHYLKAIDAROVA³**

¹Department of Oncology and Radiology, Avicenna Tajik State Medical University, Dushanbe, the Republic of Tajikistan;

²Republican Oncological Scientific Center of the Ministry of Health and Social Welfare, Dushanbe, the Republic of Tajikistan;

³Kazakh Institute of Oncology and Radiology, Almaty, the Republic of Kazakhstan

Some aspects of skin melanoma diagnostics and treatment in the Republic of Tajikistan

Relevance: Melanoma is considered one of the most aggressive tumors. It is distinguished by early and multiple metastases, often unsatisfactory outcomes, and a variety of clinical and morphological forms. Its incidence is steadily growing in the world and the Republic of Tajikistan. The official statistics reported 222 newly diagnosed cases of skin melanoma in 2018 vs. 159 in 2010. According to our figures, patients below 40 years are mostly women (56.2%), older patients are mostly men. The peak incidence is at the age of 40 and above, with the average patient age of 53. Other ages are also affected, including 1-2 cases at the age of 0-4 years.

The purpose of the study was to analyze the specifics of diagnostics, treatment, and survival rates of patients with skin melanoma in the Republic of Tajikistan and assess the errors in diagnostics and tactics at the primary healthcare level.

Results: We studied the medical records of 26 patients treated in-patiently at the Republican Oncological Scientific Center of the Republic of Tajikistan in 2017-2019. The patient age varied from 20 to 89 years, men (73.1%) prevailed, the peak incidence was at the age of 45-66 years. More than half of the patients came to treatment within two years after the onset of the disease. The disease factors included: trauma incl. surgical intervention (38.4%), hereditary factor (7.7%), spontaneous occurrence (30.7%), and precancer diseases (nevi) (23.1%). The diagnosis was verified before surgery in 14 (53.8%) cases, intraoperatively in 2 (7.7%), and post-surgery in 10 (38.5%). The tumor was localized mainly on the body (38.5%) and the lower limb (23.1%). 21 (80.8%) patients underwent various surgical interventions, 5 (19.2%) patients refused surgery. 8 (30.8%) patients had metastases at diagnosis; in 4 (15.4%), metastases appeared up to 3 years after surgery. The mortality before three years was 12 (46.2%). The 3-year observed survival was 52.1%.

Conclusion: Timely diagnostics and optimal choice of treatment in skin melanoma are of importance. A high rate of diagnostic errors at the general practitioners' level affects the overall survival of patients.

Keywords: melanoma, diagnostics, treatment, survival.

Introduction: Skin melanoma is a malignant neuroectoderm tumor originating from melanocytes (pigment cells). Melanoma is regarded as one of the most aggressive tumors. It is distinguished by early and multiple metastases, often unsatisfactory treatment outcomes, and a variety of clinical and morphological forms [1]. The incidence of melanoma is steadily growing throughout the world. On average, it accounts for up to 3% in the structure of malignant neoplasms; in Russia, it accounts for 3.9% with an average annual increase of up to 5% (in the US – 4%). The incidence differs by region significantly. The highest incidence of skin melanoma is registered among the white population of Australia, New Zealand (33.3-33.6 per 100 thousand persons), and Scandinavian people (24.7-29.6 per 100 thousand persons); the lowest rates are observed in Qatar, Saudi Arabia, India, Pakistan, and Korea (up to 0.30 per 100 thousand persons) [2, 3].

According to the literature, skin melanoma is more common at the age of 30-60 years; the average age of patients is 52 years [4-6]. Melanoma accounts for no more than 10% of all cases of skin cancer but is the cause of 80% of deaths from skin cancer. According to various authors, 22-57% of melanoma cases are registered in the head and neck area [5, 6].

The important factors for melanoma onset and development include heredity, UV radiation, body type (fair skin, red hair, etc.), hormonal state, and pre-malignant conditions.

There are four main types of melanoma: 1) surface-spreading; 2) lentigo melanoma; 3) nodal; 4) acral.

The tumor's aggressiveness depends on its localization. In men, the worst prognosis is observed with tumor localization on the upper limbs, in women – with genital lesions [7].

In cancer diagnostics, early detection is the main unresolved task. N.N. Blokhin Russian Cancer Research Centre of RAMS reported that 82.4% out of 159 patients first diagnosed with melanoma had invasion levels III-V; 30% had regional metastases to the lymph nodes during treatment [1]. A histological examination must include the identification of a histological type of tumor, the invasion level by Clark, the tumor thickness by Breslow, cellular type of the structure, background neoplasms, the presence of ulceration, the pigmentation degree, the severity and location of reactive infiltrate, and the presence of mitoses.

The issue of false-negative and false-positive melanoma diagnosis remains relevant. Special assessment systems were adopted to facilitate differential diagnostics of melanoma (WHO Melanoma Program, 1994); ABCD algorithm, 7-point Glasgow system, and FIGARO rule) [8, 9].

The treatment of skin melanoma according to the NCCN protocols (2019) depends on the degree of tumor prevalence. The treatment includes: at stages 0-IA-IB-IIA – the first-line therapy (wide surgical excision, sentinel lymph node biopsy followed by selective lymphadenectomy), at stage IIB – the second-line (adjuvant chemotherapy, immunotherapy, regional circulatory disorders) and the third-line therapy (radiation therapy, Mohs micrographic surgery), with unresectable and metastatic forms at stage III-IV – the tar-

geted therapy with the inhibitors of immune control points (Ipilimumab, Pembrolizumab/Trabectedin). During the last year, we significantly reduced the treatment of patients with interferon (Reaferon) due to its low efficiency.

This assumption was taken as the basis in the development of new skin melanoma treatment standards in the Republic of Tajikistan.

According to the literature, 3-year overall survival is 97% with stage IA vs. 33% with stage IV; one-year mortality is 25% [10].

The purpose of the study was to analyze the specifics of diagnostics, treatment, and survival rates of patients with skin melanoma in the Republic of Tajikistan and assess the errors in diagnostics at the primary healthcare level.

Materials and methods: The reports on newly registered cases of skin melanoma for 2010-2018 were studied. Twenty-six cases of skin melanoma were analyzed by a retrospective study of medical records (outpatient records, case histories) and prospective follow-up of 13 patients with skin melanoma treated at the Republican Cancer Research Center of the Republic of Tajikistan (RCRC RT) in 2017-2019.

The differential diagnostics of skin lesions was based on the analysis of complaints, medical history, lab test results, physical examination, dermoscopy, and cytological

examination of smears. The final diagnosis was established based on the histological examination of excised material.

Surgery was the main treatment method for primary skin melanoma and/or its regional metastases. The width of the excised graft, i.e., the resection borders, depended on the invasion level and the tumor thickness. Long-term results were assessed by the timing of relapse and the overall observed survival (OOS).

Results and Discussion: The data collected by the Republican Center for Medical Statistics and Information showed an upward trend in skin melanoma incidence in the Republic of Tajikistan. 159 patients were registered with skin melanoma in 2010, 18 of them – newly registered, vs. 222 patients and 33 new cases in 2018, meaning an 83% growth (Figure 1). The peak incidence was at the age of 40 years and older; the average age was 53 years. Other ages were also affected, including 0-4 years (1-2 cases per year). Rural residents made up 65.70% of the patient population. Eight (2010) to 17 (2018) deaths from skin melanoma were registered each year. Among the newly registered cases, the staging (pT) of the disease was as follows: stages I-II – 65%, stage III – 25%, stage IV – up to 10%. In recent years, the incidence amounted to 2.4 per 100 thousand population.

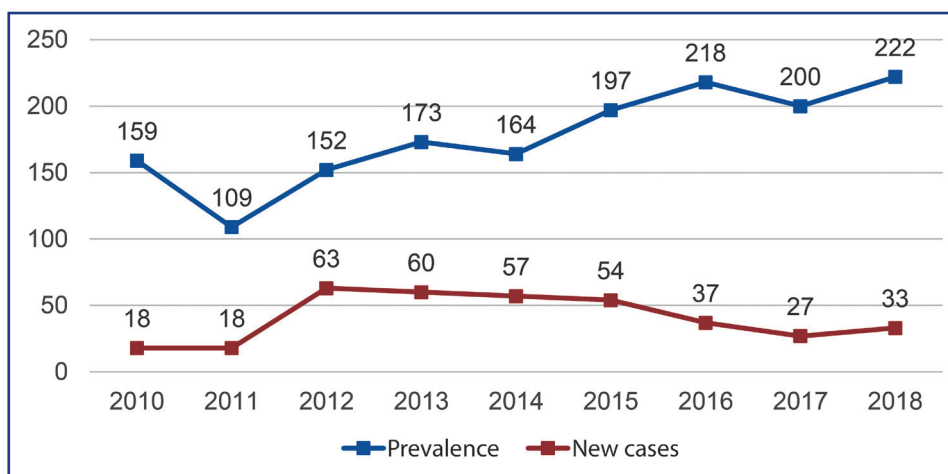


Figure 1 – Trends in skin melanoma incidence in the Republic of Tajikistan, 2010-2018, abs. figures

In the study period (2017-2019), the incidence has slightly increased, judging by the number of appeals of patients with skin melanoma to the RCRC RT.

The study included 26 patients with skin melanoma who contacted the RCRC RT outpatient clinic and were treated in the RCRC RT General Oncology Department. The patients were aged 20 to 89 years; of them, 19 (73.1%) were male, and 7 (26.9%) female. The average age was 50 years; of them, 54 years in men and 46 years in women. The peak incidence was at the age of 45-66 years.

Four (15.3%) patients appealed within six months from the onset of the disease, 8 (30.7%) – within one year, 14 (53.8%) – within two years. This indicates a late appeal by patients and a lack of attention to this group of PHC doctors.

Typical complaints included pain at the neoplasm site – 4 (15.3%) patients, itchy skin – 3 (11.5%), recent discoloration of the neoplasm – 5 (19.2%), bleeding – 5 (19.2%), and ulceration – 2 (7.7%). Six (23.1%) patients

had no complaints at appeal except for the skin neoplasm.

The identified factors of onset or manifestation of the disease included: the spontaneous development of the disease, not associated with any factors – in 8 (30.7%) patients, trauma – 5 (19.2%), hereditary factor – 2 (7.7%), hormonal disorders (decrease in thyroid hormones and TSH) – 4 (15.3%), trauma, including surgery (resection of the nail plate) – 5 (19.2%) patients. In 6 patients (23.1%), the development of melanoma was associated with former pre-malignant conditions (nevi).

Instrumental methods to clarify the diagnosis, in addition to physical examination, were applied by indications, sequentially, depending on the advancement of the process. These methods included a chest x-ray, ultrasound of the abdominal organs, dermoscopy, computed tomography, magnetic resonance imaging, as well as cytological and histological studies. Some patients were also tested for lactate dehydrogenases.

The diagnosis was verified by cytological examination before surgery in 14 (53.8%) patients, by urgent histological examination during surgery – in 2 (7.7%), and by scheduled histological examination after surgery – in 10 (38.5%) patients. Three (11.5%) tumors underwent immunohistochemical examination. Morphologically, epithelial-like and spindle-cell tumors prevailed.

The tumor was localized on the trunk in 10 (38.5%) cases, on the head and neck – in 6 (23.1%), on the lower limb – in 6 (23.1%) and on the upper limb – in 4 (15.4%).

The distribution by stage is provided in Table 1. The high rate of neglect (57.7%) corresponded to the average national cancer neglect rate.

Table 1 – Distribution of patients with skin melanoma by disease stage

Stage	Number of patients	% ± m
I	5	19.2 ± 1.55
II	6	23.1 ± 1.65
III	3	11.5 ± 1.25
IV	12	46.2 ± 1.96
Total	26	100.0 ± 0.0

In total, 21 patients underwent surgical treatment; of them, excision of the tumor for diagnostic and treatment purposes – 7, wide excision of the tumor with plastics of the removed graft – 1, wide excision of the tumor – 6, non-radical excision (in institutions of the general medical network) – 4, lymphadenectomy – 2. Five patients refused surgery for various reasons.

After surgery, the patients with multiple metastases in the lymph nodes and distant metastases received immunotherapy (Reaferon – 20 million IU/m² IV for 5 days during 4 weeks, then 10 million IU/m² subcutaneously 3 times a week for 48 weeks) and chemotherapy (dacarbazine 250 mg/m² IV for 5 days daily at stage II-III, polychemotherapy according to the BOLD scheme at stage IV).

The frequency of metastasis was analyzed at appeal and diagnosis and at different times after surgery. Seven (26.9%) patients had no metastasis neither before treatment nor during follow-up period. Metastases to regional lymph nodes were detected in 8 (30.8%) patients at appeal; in 4 (15.4%) patients, they were found after surgery by clinical and instrumental methods. In 2 (7.6%) patients, distant metastases to the lungs, liver, and spine in combination with regional metastasis were detected at clarification of the diagnosis before surgery. Distant organ metastases were detected 1 to 36 months after surgery; of them, one patient had metastases in the lungs, thyroid gland, and skin one month after surgery; 1 had spinal metastases 2.7 months after surgery, another – 11 months after surgery; two patients had metastases in the liver, lungs, and brain detected 2 and 3 years after surgery.

Long-term survival was monitored in 25 (96.1%) patients. The 3-year OOS was 52.1%. Twelve patients died of disease progression; of them, 7 (26.9%) – within six months, 3 (11.5%) – within one year, 1 (3.8%) – within two years, and 1 (3.8%) – within three years. One patient was out of follow-up; 13 (50%) patients (11 males and two females) were alive after three years.

Many authors used to attribute skin melanoma to 'fatal,' highly malignant tumors, describing it as a tumor with ulceration, bleeding, necrosis on the surface. That is, the

macroscopic manifestations of late, advanced stages of melanoma development were treated as its diagnostic symptom [11, 12]. The modern view on melanoma the aggressiveness has changed. W.H. Clark supposed that the aggressive forms of melanoma (the nodular melanoma and *Lentigo maligna* melanoma) are the final stage in the development of long-term surface forms of melanoma [13]. This supposition is increasingly confirmed.

The transition of the 'horizontal' into 'vertical' phase occurs gradually, within 3-7 to 10-15 years. However, the timely diagnostics of early curable melanoma is rare. In our study, more than 57% of patients have been admitted with stages III-IV of the disease. The literature reports the neglect rate (diagnosis at stages III-IV) of 23 to 82% [12, 14]. One of the ways to improve the early detection of skin melanoma is to attract the attention of PHC doctors and dermatologists to the "syndrome of small signs" of minimal melanoma, as described by L.V. Chervonnaya [1]. Such signs include:

- the onset of subjective sensations in the area of skin spots such as itching, a feeling of spreading, inconvenience;
- increase of the spot, the appearance on it of one or more plaque-shaped formations, slightly protruding above the skin level;
- the surface of the plaques is smooth, shiny, with a loss of skin pattern;
- change in the plaque color intensity compared to the spot;
- swelling in the form of a pinkish circle around the pigment spot.

The identification of a more comprehensive risk group for melanoma based on a multicenter study could improve early detection and efficient prevention. The latter becomes more relevant in the absence of preventive examinations and programs for early detection of skin tumors.

According to the literature [4-6], the incidence reaches its peak after the age of 50. This is confirmed by our data (45-64 years; average age – 50 years). According to most authors [4, 5], women prevail among patients with melanoma (1.5–2:1). In our study, female patients made 26.9% of patients. Further study is required to clarify the reason for this discrepancy.

According to several authors [1, 2], melanoma can occur both against the background of pigmented nevi and spontaneously on unchanged skin. Contributing factors are excessive UV insolation and trauma. In our study, 8 (30.7%) patients developed a melanoma on unchanged skin, 6 (23.1%) cases – against the background of pigmented nevi. Trauma in 10 (38.5%) patients and insolation in 4 (15.4%) patients served as provoking factors.

Tumor localization can influence disease prognosis. According to the literature [1], the worst prognosis is observed in men with the tumor localization on upper limbs (3 patients in our study) and in women with genital lesions (not presented in our study). In total, our material cannot serve to confirm the above statement.

Various authors [2, 7, 15] pointed out inadequately performed surgical interventions or other treatment (ointments, physical procedures, etc.) in PHC institutions and cosmetology centers (15 to 36% of cases). In our study, inadequate surgery was reported in 4 (15.4%) cases, improper conservative treatment – in 2 (7.7%) cases. Both had a definite impact on the disease prognosis. In total, in our study, 57.7% of patients had an advanced stage at admission due to erroneous diagnostics and inadequate treatment.

During skin melanoma diagnostics, we strictly adhered to the rule that prohibited an incision tumor biopsy since it could promote rapid dissemination and peracute metastasis of the tumor due to a high migration ability of atypical melanocytes. A histological examination should identify the histological type of tumor, the cellular type of melanoma, the invasion level by Clark, and the tumor thickness by Breslow. In our study, 12 patients underwent histological examination describing the tumor type and the invasion level. Seven (58.3%) of them had an epithelial-like tumor, three (25%) had the spindle-cell tumor, and two (16.7%) delivered a mixed-cell variant.

Surgery is the main generally accepted method of skin melanoma treatment. The previous 30 years evidenced a transition from wide to economical excisions [1, 2]. Six prospective clinical studies conducted from 1985 to 2015 to determine the resection border revealed no difference in the long-term outcome associated with the tumor resection with a margin of 2 or 4 cm from the edge of the neoplasm. Based on this generalization, the following resection boundaries were recommended depending on the tumor thickness [8]:

- T *in situ* – 0.5 cm
- < 2 mm – 1.0 cm
- 2 – 4 mm – 2.0 cm
- > 4 mm – 2.0 cm.

For nodular melanomas more than 2 mm thick, Chissov et al. recommend a wide excision of the neoplasm with a margin of 3-5 cm from the visible edges of the tumor, followed by plastic closure of the defect [16]. In the horizontal phase of growth, melanoma can be cured by surgery in 97-100% of cases [10]. In the vertical stage of melanoma growth, surgical treatment is supplemented by immunotherapy due to unfavorable prognosis. Based on the experience, we excised the tumor with local tissue rearrangement in 7 (30%) out of 21 cases. In 10 (47.6%) cases, we made a wide tumor excision with advanced flap grafting. 4 (19%) patients underwent non-radical tumor excision in PHC institutions before admission to the RCRC RT. 8 (38.1%) patients underwent simultaneous lymphadenectomy.

In recent years, we use an electric knife to excise tumors at certain locations (head, neck, trunk), forming a preliminary coagulated ridge along the inner perimeter of the excision. Dacarbazine (250 mg/m² IV for 5 days daily at 3-week intervals) was usually prescribed as adjuvant therapy. Polychemotherapy prescribed with advanced stages included Dacarbazine + Cisplatin with the addition of Fotemustine or Lomustine, alone or in combination with Tamoxifen. Interferons and cytokines (Reaferon and Proleukin) were prescribed as immunotherapy.

In Russia, the five-year survival for this group of patients is 52.2%. In our study, the 3-year OSS, equal to 52.1%, testified to the low effectiveness of the therapeutic measures taken and the neglect of the disease.

Conclusions:

1. The diagnostics and treatment of skin melanoma remain an acute problem in the Republic of Tajikistan due to a high share of neglected cases and low efficiency of treatment (survival).

2. Many errors in diagnosis and inadequate treatment at the PHC level require complex actions to increase cancer alertness, the awareness of general practitioners about the modern methods of diagnostics and treatment of malignant neoplasms.

3. The identification of risk groups for melanoma would contribute to early detection and the related reduction in metastasis, relapse, and mortality.

4. The use of new diagnostic methods (expert system, ploidyometry, etc.) can improve the diagnostics and prognosis of the disease by personalizing the treatment.

5. The low 3-year survival of treated patients necessitates advanced approaches to treating melanoma, including a personalized approach.

References:

1. Chervonnaya L.V. *Pigmentnyye opukholi kozhi [Pigmented skin tumors]*. - Moscow: GEOTAR-Media, 2016. – 224 p. [in Russian];
2. Lamotkin I.A. *Klinicheskaya dermatoonkologiya: Atlas [Clinical Dermato-Oncology: Atlas]*. - Moscow: BINOM. Knowledge Laboratory, 2014. – 499 p. [in Russian];
3. The World Health Organization/International Agency for Research of Cancer. GLOBOCAN database (September 2018) // gco.iarc.fr/today/home. 01.04.2020;
4. Tsao H., Atkins M.B., Sober A.J. *Management of cutaneous melanoma* // *N. Engl. J. Med.* – 2004. – Vol.351. – P. 998–1012;
5. Markovic S.N., Erickson L.A., Rao R.D. et al. *Malignant Melanoma in the 21st Century, Part 1: Epidemiology, Risk Factors, Screening, Prevention, and Diagnostics* // *Mayo Clin. Proc.* – 2007. – Vol. 82, №3. – P. 364–380;
6. Sirvan S.S., Eren H.I., Yazar S.K., Gunenc A.C., Yesilada A.K., Irmak F., Tuncel D. *Approach to Patients with Malignant Melanoma of Unknown Primary Origin // SiSli Etfal Hastanesi Tip Bulteni [The Medical Bulletin of Sisli Hospital]*. – 2019. – 10.14744/SEMB.2019.52333;
7. Garbe C., Peris K., Hauschild A. et al. *Diagnostics and treatment of melanoma. European consensus-based interdisciplinary guideline – update 2016* // *Eur. J. Cancer.* – 2016. – Vol. 63. – P. 201–217;
8. Testori A., Ribero S., Bataille V. *Diagnostics and treatment of in-transit melanoma metastases* // *Eur. J. Surg. Oncol.* – 2017. – Vol. 43, N. 3. – P. 544–560;
9. Avril M.F., Cascinelli N., Cristofolini M. et al. *Clinical diagnostics of melanoma* // WHO Melanoma Programme Publications. – 1994. – Vol. 3. – P. 28;
10. Elmore J.G., Barnhill R.L., Elder D.E. et al. *Pathologists' diagnostics of invasive melanoma and melanocytic proliferations: observer accuracy and reproducibility study* // *Br. Med. J.* – 2017. – Vol. 357. – P. 2813;
11. Anisimov V.V., Semiletova Y.U.V., Barchuk A.S., Radzhabova Z.A. *Aktual' nye voprosy khirurgicheskogo lecheniya bol' nykh pervichnoy melanomoy kozhi [Topical issues of surgical treatment of patients with primary skin melanoma]* // *Siberian Journal of Oncology.* – 2010. – № 2. – P. 55–58 [in Russian];
12. Demidov L.V., Sokolov D.V., Bulycheva I.V. et al. *Sovershenstvovaniye metodov diagnostiki melanomy kozhi [Improvement of methods for diagnosing skin melanoma]* // *Bulletin of the N.N. Blokhin Russian Cancer Research Center RAMS.* – 2007. – № 1. – P. 36–41 [in Russian];
13. Clarck W.H., From L., Bernardino E.A., Mihm M.C. *The histogenesis and biologic behavior of primary human malignant melanoma of the skin* // *Cancer Res.* – 1969. – Vol. 29. – P.705-727;
14. Ufimtseva M.A., Petkau V.V., Shubina A.S. et al. *Algoritmy ranney diagnostiki melanomy kozhi [Algorithms for early diagnosis of skin melanoma]* // *Lechashchiy vrach [Attending doctor]*. – 2016. – № 12. – P. 12-24 [in Russian];
15. Baltabekov N.T., Abisatov K.H.A., Kaydarov B.K., Ivakin A.A. *Oshibki pri khirurgicheskoy lechenii melanomy kozhi [Errors in surgical treatment of skin melanoma]* // *Vestnik khirurgii Kazakhstana [Bulletin of Surgery of Kazakhstan]*. – 2009. – № 1 (17). – P. 22 [in Russian];
16. Chissov V.I., Romanova O.A., Moiseyev G.F. *Rannyyaya diagnostika melanomy kozhi: Rukovodstvo dlya vrachey [Early diagnosis of skin melanoma: A guide for doctors]*. – M.: Yulana Trade, 1998. – 32 p. [in Russian].