UDC: 616-006:615.849

M.A. KAINAZAROVA[1]

[1]Kazakh Institute of Oncology and Radiology, Almaty, the Republic of Kazakhstan

Use of electrosurgery in the clinical practice of an ophthalmic surgeon

The article briefly describes the history of using electrosurgery in various fields of surgery. The features of the coagulation on various tissues of the organ of vision are described.

Force FX coagulator by COVIDIEN was used as a test apparatus during operations on 26 patients with eyelid, conjunctiva and orbital tumours. The apparatus showed reliable technical performance at all stages of surgery in all 26 patients. Coagulation for the purpose of haemostasis was achieved quickly without necrosis of the tender tissues of this anatomical region. During orbital surgery, haemostasis was reliable in 5 (19%) patients; no additional haemostatic agents were required. In 17 (65.4%) patients with various neoplasms of skin of the eyelids and the periocular region, reconstructive and plastic surgery resulted in good engraftment of cutaneous, cutaneous-fascial, and cartilaginous flaps. 3 (11.5%) of patients with recurrent tumours after radiation therapy had marginal necrosis of transplanted grafts. Still, the second operation was not required; the healing went successfully. In 4 (15%) patients with pigmentary progressive conjunctival nevuses, coagulation was used to block the "feeding" vessels. In all cases, the conjunctiva remained pink, smooth, with no signs of ischemia in the postoperative period.

Force FX coagulator is also suitable for outpatient surgery.

Keywords: *electrocoagulation, Force FX coagulator, eyelid skin tumours, conjunctiva tumours.*

Introduction. In 1909, Doyen was the first to use the method of tissue electrocoagulation. Dissection of tissues by electric current was first described by Cherni in 1910. V.N. Shamov applied electrosurgery in the treatment of malignant tumours in 1910-1911 in Russia [1]. The possibilities of using electrosurgery in surgery, oncology, gastroenterology, urology, stomatology, ophthalmology and other fields of clinical medicine have expanded due to development of radio electronics and improvement of technical facilities. Preliminary coagulation of commissures and synechiae ensures their bloodless dissection in abdominal and thoracic surgery. Electric knife allows dissecting serous and muscular membrane of stomach and intestine, to coagulate vessels of submucous layer in the anastomosis formation zone. Loop electrodes introduced with fiber optics through endoscope into various parts of the gastrointestinal tract allow performing polypectomy and arrest bleeding by coagulation of vessels. The method of endoscopic papillotomy has been introduced into clinical practice. High-frequency currents are used in neurosurgery to dissect brain tissues, remove tumours located in hard-to-reach areas, and treat the tumour bed by electrocoagulation. Transurethral electroresection of prostatic adenoma, pathological formations of bladder and urethra is used in urology. Use of specified methods in operational oncology ensures the destruction of tumour cells by electrocoagulation, and the coagulation of lymphatic and blood vessels prevents tumour cell expansion [1].

Heat created in tissues by the passing current is the main factor of impact of high frequency currents on tissues. This current is supplied by different generators.

Monopolar and bipolar techniques are distinguished by the method of application of high frequency current. The surgeon's working tool is the active electrode, while the passive electrode ensures electrical contact with the patient's body outside the operating field during the most common monopolar technique [2].

In the bipolar technique, both outputs of generator are connected to active electrodes, i.e., with the so-called jaws of bipolar tweezers insulated from each other. In this case, the thermal action is provided by two active electrodes in a confined space between them.

The tissues are cut by applying a monopolar effect. The rupture effect is achieved due to the explosive action of vapour formed instantaneously in the tissue fluid adjacent to the active electrode.

Coagulation is also used to arrest bleeding; it is achieved with the help of bipolar forceps. The bleeding vessel is seized with such forceps; the temperature between its jaws increases at the moment of switching on the electric current to form thrombus. The active monopolar electrode is also used to arrest bleeding. For this purpose, the monopolar electrode attached to the haemostatic forceps is applied to the vessel for a short period of time to form the thrombus immediately. The coagulation of bleeding vessels reduces the time of surgery and ensures better wound healing [2].

Fulguration of tissues is used to destruct them, for example, to prevent papillomatous growth in oncological practice. This effect is achieved by longer coagulation or the use of higher current. Burns of tissues outside the operating wound (in a zone of loose attachment of a passive electrode) are a possible complication due to the use of high-frequency currents in surgery. The monopolar electrosurgery can cause coagulation of vessels and nerves located nearby due to local heat release if there are foreign metal bodies in tissues on the path of the electric current [1].

The use of monopolar and bipolar coagulation is increasing in ophthalmic oncology, in particular, in surgery to remove tumours of eyelid skin and eye adnexa [4].

Our experience has shown reliability and ease of use of Force FX multi-purpose coagulator by Covidien (Figure 1).

Force FX 300 W microprocessor coagulator has Valleylab computer control technology; it provides much more automaticity in customization to different types of tissues and a truly instantaneous response to surgeon's needs. Force FX coagulator has three cutting (dissection) modes with a minimal damage of incision edges.

Figure 1 - Force FX microprocessor coagulator

1) Low-cut differs by absence of electrical discharges in the air between the electrode and the tissue.

2) Pure Cut is a cutting mode without haemostasis, with preservation of set power in a wide range of electrical resistance of tissues what is of great importance in urological, gynaecological surgery.

3) The cutting mode with haemostasis is suitable for any indices of total resistance. The number of regimens was reduced on purpose for the convenience of surgeon – the so-called "Instant Response" regimen. The doctor only sets the required power. The control panel of the device is very friendly even for the junior surgical staff [3].

There are also two modes of coagulation:

1) Contact Coagulation (Desiccation) with no tissue charring during haemostasis. Drying of tissues at low power allows avoiding adherence of coagulation eschar to monopolar electrode surface at drying.

2) Non-contact coagulation (Fulguration & Spray). In traditional generators, coagulation is accompanied by constant "electronic paths" (simple channelling) in the ionized air between the electrode and the tissue surface. Thus, the sparks actually fall on the same places causing hypercoagulation and insufficiently affecting the surrounding surface. This device is equipped with Valleylab electronic channel destruction system that improves the initiation of non-contact sparking by adjusting the amplitude and frequency of the electric current and increases the gap between the electrode and the tissue thus increasing the safety of the coagulator usage.

Generator determines tissue impedance between forceps jaws and only then switches on with a delay suitable for the specific surgeon (0.5-2.5 sec.). [3].

Materials and methods. Head and Neck Tumour Department of KazIOR has performed testing of Force FX Coagulator during ocular organ surgeries on 26 patients with various tumours of eyelid skin, conjunctiva, eye socket.

Features of eyelid structure: very thin skin (the thinnest skin of human body is on the eyelids), a rich blood network, proximity to cornea, required a particularly delicate treatment during electric knife usage. In addition, it was necessary to comply with ablastics, that is, to retreat from the visible edges of the tumour at least by 5 mm. Taking into account the initial deficiency of eyelid tissues, with pronounced tumour infiltration or pigmentation of eyelid skin, it was necessary to retreat from tumour edges even more what was another difficult task for ophthalmic surgeon. It was necessary to remove completely the tumour with the capture of "healthy" tissues and save at least part of the tissues (conjunctiva, cartilage, tear ducts) for the subsequent reconstructive-plastic surgery. The surgeon had to avoid "overburning" of delicate skin of the eyelid or conjunctiva in order to avoid marginal necrosis of the transplant in the postoperative period.

Two coagulation modes were used: monopolar coagulation in the 10-12 Hz mode for tissue cutting and coagulation of small vessels, and bipolar coagulation was more often used during treatment of soft tissues of eye socket and coagulation of larger vessels.

Surgeries to remove eye socket tumours have to follow strict requirements due to the anatomy of the eye socket itself, and to the peculiarities of its topographic relation with the adjacent areas. It is necessary not only to perform the ablastic tumour removal, but also to preserve the eye functions, as well as to obtain a good cosmetic effect in a postoperative period [4]. A reliable monopolar and bipolar coagulation at the stage of tumour mobilization helps the surgeon to cope with set tasks.

Results. The described apparatus has proven to be reliable and ease to use during separation of soft tissues of eye socket, eyelid skin, and conjunctiva. Coagulation for the purpose of haemostasis was achieved quickly and, what's more important, without necrosis of the delicate tissues of that anatomical region.

During orbital surgery, haemostasis was reliable in 19% (n=5) patients; no additional haemostatic agents were required. Coagulated tissues were viable without necrotic and inflammatory changes in the early postoperative period.

In 65.4% (n=17) patients with various neoplasms of skin of the eyelids and the periocular region, reconstructive and plastic surgery resulted in good engraftment of cutaneous, cutaneous-fascial, and cartilaginous flaps.

Of those, insignificant marginal necrosis of transplanted grafts was observed only in 11.5% (n = 3) of patients with recurrent tumours after radiotherapy. However, that did not require a repeated surgery; primary intention was finally enough for healing.

Coagulation was used to block the "feeding" vessels for 15% (n=4) of patients with pigmentary progressive conjunctiva nevi. In all cases, the conjunctiva remained pink, smooth, with no signs of ischemia and black mark during the postoperative period.

Approximately 15-20% of outpatient surgeries are performed in surgery [5]. In our practice, surgical treatment of tumours of eyelid skin at early stages (T1-T2) can be performed by the so-called "minor surgery".

Conclusions. Force FX microprocessor coagulator showed a reliable performance at all stages of surgical manipulation in all 26 patients with neoplasms of the eyes. It allows recommending the apparatus for wider clinical practice in various areas of surgery.

This device is especially suitable for outpatient surgery due to its small size and ease of use.

Clinical case

Patient V., 56 years, admitted to the Head and Neck Tumour Department with the diagnosis: basal cell carcinoma of the lower eyelid of the right eye with extension to the cartilage and posterior fornix of conjunctiva of the right eye, T2N0M0 St II (Figure 2).

Figure 2 - Photo before surgery

The surgery: a wide excision of the tumour of the lower eyelid skin with microsurgical plastic reconstruction of the postoperative defect with a cartilaginous flap from the ear auricle and a skin flap from the upper eyelid was performed on May 17, 2017.

Figure 3 shows the stage of the surgery - isolation of the tumour with the Force FX coagulator in the Low-Cut cutting mode.

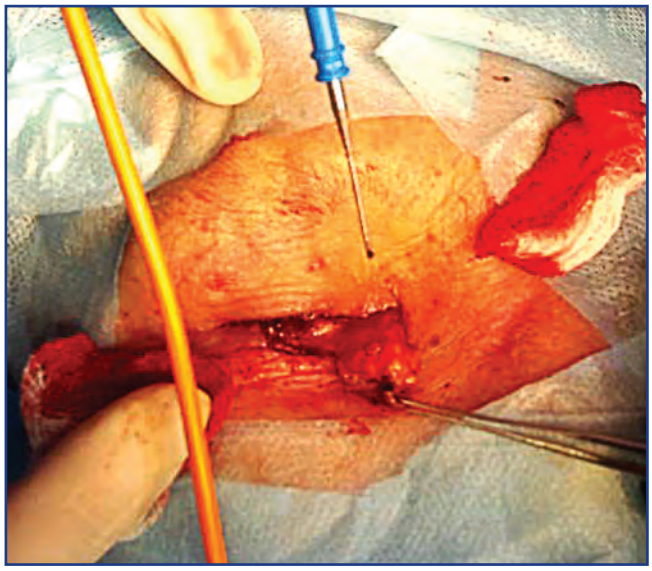

Figure 3 - One of the stages of surgery

Figure 4 shows the appearance of the same patient with a good functional and cosmetic result on the 7th day after the surgery.

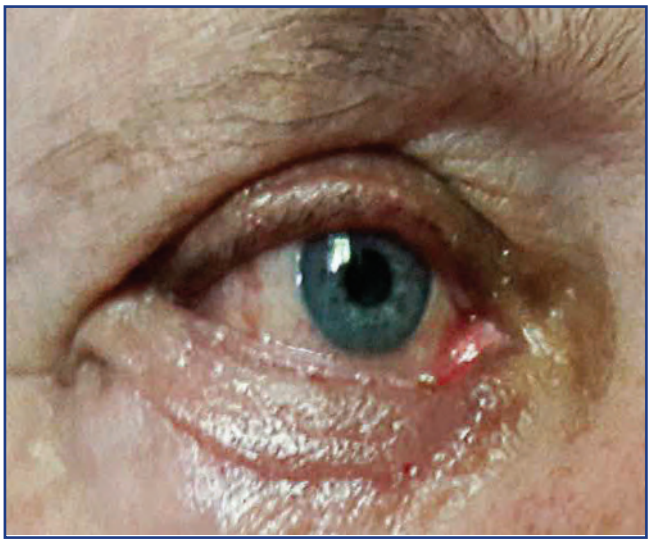

Figure 4 - 7 days after surgery

References

1. Elektrokhirurgiya // Meditsinskaya entsiklopediya [Electric Surgery // Medical enciclopaedia]. http://medlechit.ru/index/ehlektrokhirurgija/0-744. 19.12.2017

2. Natal'ya Nedoseykina. Energeticheskie metody ligirovaniya sosudov [Energy methods of vascular ligation] // http://www.myshared.ru/ slide/491908/. 19.12.2017.

3. FORCE FX Coagulator // www.nda.ru/electrosurgery/ force-fx.html. 19.12.2017

4. Brovkina A.F. «Oftal'moonkologiya» Rukovodstvo dlya vrachey [Ofthalmic oncology. Manual for doctors]. – Moskva, «Meditsina», 2002. – 107 c.

5. Peypl A.D. Plasticheskaya i rekonstruktivnaya khirurgiya litsa: Rukovodstvo dlya vrache [Plastic and reconstructive face surgery: Manual for doctors]. –3rd ed. – M: BINOM, 2013.