UDC: 616.381-006.6-089

F.G. ULMASOV[1], M.D. DZHURAEV[1], A.A. YUSUPBEKOV[1], D.M. EGAMBERDIEV[1]

[1]Republican Cancer Research Center of the Ministry of Health of the Republic of Uzbekistan, Tashkent, the Republic of Uzbekistan

Surgical treatment of locally advanced tumors of the retroperitoneum

The article discusses the immediate and long-term results of surgical treatment of 208 patients with non-organ tumours of the retroperitoneal space that underwent surgical interventions. The nature of tumours was malignant in 152 (73.1%) cases, and benign – in 56 (26.9%) cases. Most of the patients were below 60 years – 188 (90.4%). This fact – the development of non-organ tumours mainly in patients of working age – makes this problem particularly significant from the socio-economic point of view. 64.8% of patients underwent radical surgery, 26.7% of patients – palliative surgery, and 8.3% of patients – cytoreduction. In 52.8% of cases, the operation was combined. General intra- and postoperative complications accounted for 16.4%, and postoperative mortality – 2.4%. 5-year survivability of patients with benign tumours reached 83.3%, and with malignant tumours – 12.6%. The same indicator after a radical operation was 41.3%, and after a non-radical operation – 9.6%. Relapses within 5 years after surgery for a malignant tumour occurred in 73.7% patients, and after a benign tumour – in 26.3% of patients.

Keywords: *retroperitoneal tumours, locally advanced tumours of the retroperitoneum, combined operation, survival, complications.*

Introduction. Retroperitoneal tumours (RPT) develop as neoplasms from soft tissues of retroperitoneum. RPT belongs to soft tissue sarcomas and make 10-15% of them [1]. The specific weight of RPT among oncological pathologies is 0.2-0.4%. RPTs are a heterogeneous group of tumours classified according to microscopic signs, the degree of tissue differentiation and biological potential. Histogenetically, RPTs can be divided into 3 main groups: Group 1 – tumours of mesodermal origin, 2 – tumours of neurogenic origin, 3 – tumours from embryonic remains (cysts and teratomas). RPTs are extremely difficult in diagnostics and treatment. RPTs of mesenchymal origin are characterized by rapid and aggressive growth. RPTs produce metastases in other organs in more than 30% of cases and are often detected in the advanced stage. Existing methods of diagnostics: a contrast X-ray study of the abdominal cavity, MRI, CT, ultrasound and other studies that are conducted according to the standard – can generally characterize the primary RPT, but in more than 60% of cases give false positive information about the degree of tumour germination in neighbouring organs and structures, especially, in the great vessels [1].

In more than 40% of cases, the scope and tactics of surgical intervention are changing after the intraoperative revision. Therefore, the methods of diagnostics and surgical treatment of RPT shall be reviewed. Purpose of this study is to improve the results of surgical treatment of locally advanced RPTs.

Materials and methods. 309 patients with inorganic retroperitoneal sarcoma were treated in the department of abdominal surgery of the Republican Cancer Research Center in 2006-2016. 208 (67.3%) patients underwent surgery: 46 (22.2%) – for benign tumours and 162 (77.9%) – for malignant tumours. 115 (61%) of them were men and 93 (39%) – women. The patients were aged 16 to 77.

Most of the patients (n=188, 90.4%) were below 60. According to the classification, 172 (82.7) patients had mesenchymal tumours, 28 (13.5%) – neurogenic tumours, and 8 (3.8%) – embryonic tumours.

Since 2008, the traditional studies are supplemented with MSCT with contrasting of the inferior vena cava and aorta with visceral branches was conducted to clarify the RPT diagnosis and prevalence. Diagnostic laparoscopy is also conducted to identify the real involvement of the tumour in neighbouring structures and to determine the resectability of the process and the scope of intervention, except for giant tumours that do not allow for laparoscopic examination.

Study of the local prevalence has shown that in 58 (27.8%) patients the RPT was localized in one anatomical zone, in 117 (56.2%) – in two, and in 33 (15.8%) – in three or more zones. The biggest measured size of the neoplasms was 20.2 cm in average.

Surgery is the main method of treatment of primary non-organic RPTs.

In our survey, 254 patients underwent surgery, of them, tumours were removed in 208 (81.9%) cases, and 46 (18.1%) patients underwent explorative laparotomy.

Malignant tumours amounted to 162 (77.8%) cases, benign tumours – to 66 (22.7%) cases. Of them, 64.8% of patients underwent radical surgery, 26.7% of patients received palliative care, and 8.3% of patients – cytoreductive treatment. 52.8% of patients underwent combined surgery.

The most critical moment of surgery included the isolation of the tumour and the so-called "pilot mobilization of the tumour" which included an investigatory revision, establishing the connection of the tumour with surrounding organs and vital structures, application of provisional ligatures on large vessels and making a decision on the volume and type of surgical intervention [8]. At that, a rough dislocation of even a mobile tumour into the wound is unacceptable. In 1992, the famous American surgeon P.H. Sugarbaker advised adhering to the tactics of "centripetal-directed dissection" meaning that "the surgeon must re-advance along the circumference of the tumour as when releasing the roots to extract a tree and to cut the root with an axe in the end" (Figure 1).

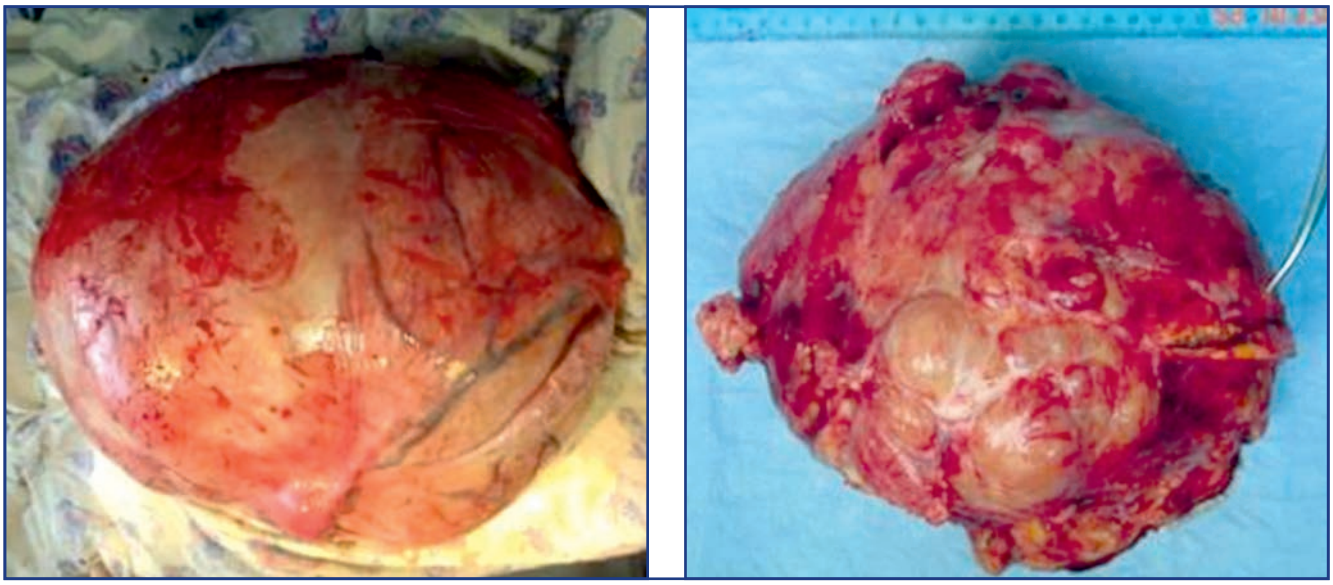

Figure 1 – Macro-preparation of a retroperitoneal tumour (RPT)

Radical surgery involves a simultaneous removal of the primary RPT and the affected surrounding structures with the mobilization of tissues outside the pseudo capsule of the tumour. If tumour process affects the neighbouring organs (kidney, spleen, pancreas, adrenal gland, stomach, duodenum, small intestine, large intestine, rectum, bladder, uterus, appendages of the uterus, vagina) or vessels feeding them, the radical surgery includes combined interventions with the removal or resection of such organs (Figure 2).

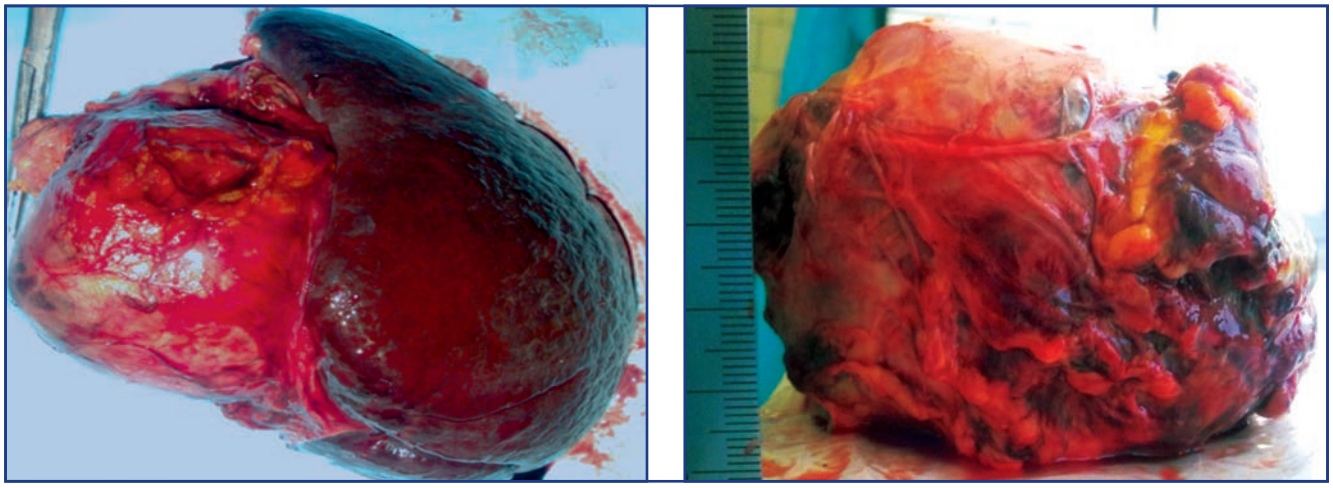

Figure 2 – Macro-preparation after a combined operation

Large arterial vessels can be resected with replacement of the defect with an allograft (Figure 3).

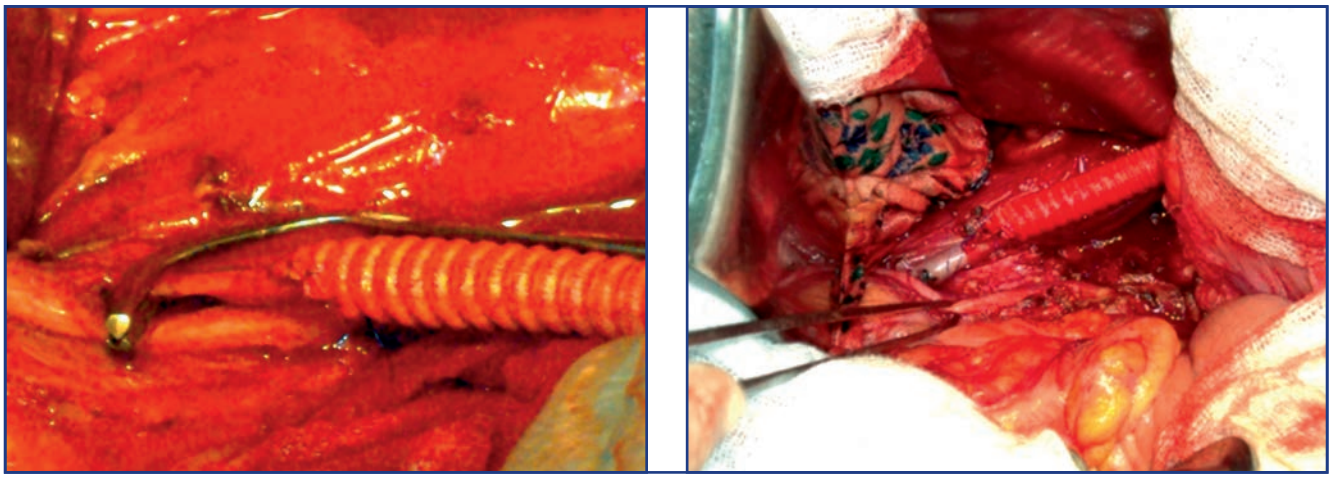

Figure 3 – Resection and iliofemoral prosthesis with tumour germination in the external iliac artery

The lower cava vena below the renal veins can be bandaged (if the only obstacle to radical removal of the tumour is its involvement in the process). According to different authors [6-8], combined radical surgery is required in 17-39% of cases of benign or malignant RPTs, and only malignant tumours up to 48.1%. In our observations, 52.8% (75) of patients underwent combined surgical interventions involving small and large intestine and their mesentery, liver, spleen, kidneys, ureters, anterior and lateral walls of the abdomen, major vessels, ovaries, bladder, pancreas and etc. In 12 (16%) cases, invasion of the great vessels was detected, of them, 3 cases of invasion into the iliac artery and vein, 4 cases – into the abdominal aorta, and 5 cases – into the inferior vena cava (in 2 patients – above, and in 3 patients – below the renal vein). In all the 3 cases of invasion into the iliac artery, the common and the external iliac artery were resected followed by ileum-femoral prosthetics. In 2 out of 3 cases of invasion into the aorta, the aorta was resected along with its prosthetic repair, and in 1 case the aortic wall was partly resected and reconstructed. In all 5 cases of invasion into the lower vena cava, the vascular walls were resected and reconstructed. In 18 (8.8%) cases, the ureter resection was performed as an element of a combined surgery, with the length of resection from 2 to 10 cm, in 10 cases – from the right side, and in 8 cases – from the left side. In 9 cases, urethro-urethro anastomosis was performed by mobilizing the ureter. In 2 cases, nephrectomy was performed taking into account the profound hydronephrosis and the length of the ureter defect. In 7 other cases the ureteral defect was 8 to 10 cm long, so we developed the unique ways to repair the defect. In the case of a defect of 8 cm on the right, we cut off appendical apophysis of blind gut with the preservation of the mesentery using the mobility of the ileocecal angle; the ureteral defect was restored by the appendical apophysis by forming the urethroappendical anastomosis. In 1 case of a defect 6 cm long, a complete mobilization of the left kidney with the renal artery and the vein and the proximal end of the ureter was achieved, thereby the left kidney as a whole was brought 6 cm down with the formation of an urethro-urethro anastomosis with nephropexy. In the third case with a similar urethral defect of 5 cm, the ureter continuity was restored by mobilizing the right angle of the bladder (Figures 4-5).

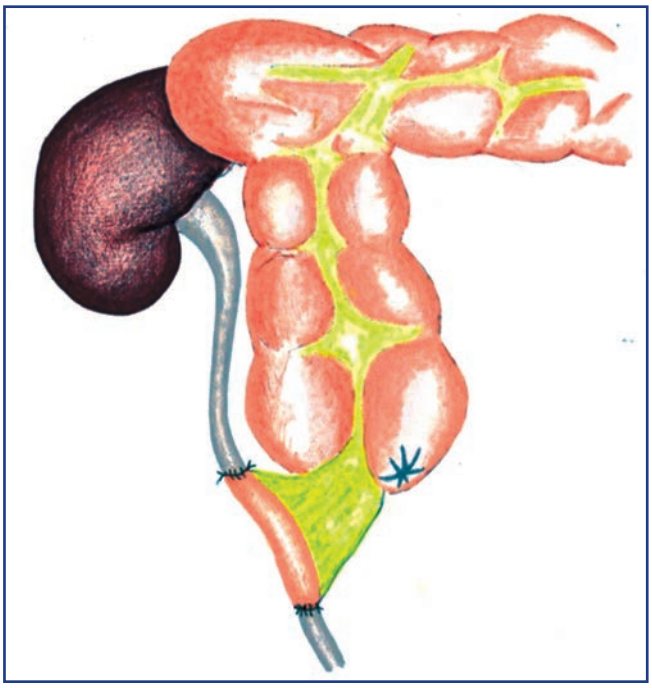

Figure 4 – Substitution of the ureteral defect with the appendical apophysis

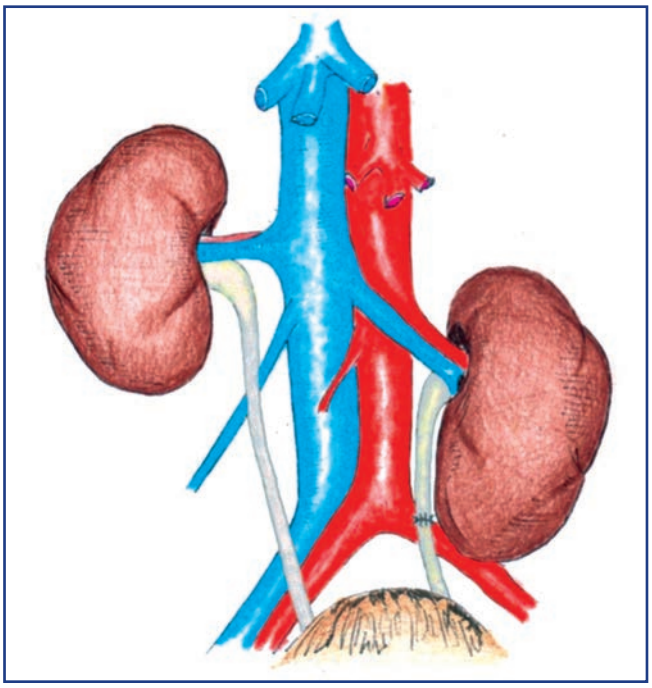

Figure 5 – Bringing down the left kidney to remove the ureteral defect

Discussion. The issue of operational complications is quite acute as they occur in 20-25% of cases, and post-surgery mortality is 8-25% according to different authors. The most serious complications include bleeding (without injury to the great vessels or as a result of injury to major great vessels); the consequences of massive transfusion of donor blood (fibrinolysis, thrombohemorrhagic syndrome). There is not standard tactic when adjacent vessels are injured, or with diffuse bleeding from the bed of the tumour, especially, inn case of intra-capsular bleeding. Surgeons often lose precious time trying to stop bleeding by electrocoagulation or suturing the bed of the tumour. We observed diffuse bleeding in 16 cases, especially intracapsular bleeding, and the attempts to coagulate or suture the bed of the tumour did not succeed. To successfully stop bleeding we used tight tamponade of the tumour bed with meter-long tampons depending on the diameter of the tumour bed, the ends of the tampons were consistently placed on the anterior abdominal wall through the counterpunctures and labelled. The tampons were removed after 6-7 days depending on the reaction of the body and the appearance of mucus. The tampons were removed sequentially: first, the most superficial, then – the middle ones, and at the end – the lowest ones.

Out of 16 patients who underwent tight tamponade, 1 female patient has died from thrombohemorrhagic syndrome. In the remaining 15 patients, the bleeding was successfully finished by tamponade. Tampons were removed after 6-7 days under short-term noninhalation anaesthesia. No complications were observed.

In general, the intra- and postoperative complications were observed in 16.4% of cases (34 patients). Of them, 24 (11.5%) patients had intraoperative complications, and 10 (4.8%) patients had postoperative complications. Intraoperative complications were as follows: during the mobilization and removal of the tumour, 16 patients developed diffuse bleeding from the tumour bed, 2 patients – massive bleeding as a result of damage to the great vessels; in 3 cases, the intestine integrity was damaged; in 2 cases - the bladder integrity, and in 1 case, the spleen integrity. Post-surgery, the complications directly related to the surgery itself included: bleeding from the bed of the removed tumour – 3 cases, external colonic fistula from the formed colo-coloanastomosis – 1 case, paralytic intestinal obstruction – 2 cases, pancreatitis – 2 cases, thromboembolism - 1 case, acute cardiovascular insufficiency - 1 case. 1 (0.4%) female patient has died during surgery from acute cardiovascular insufficiency due to continuing bleeding and thrombohemorrhagic syndrome. 5 patients died post-surgery, of them, 2 – from intraperitoneal bleeding, 1 – from thromboembolism, 1 – from heart attack, and 1 – after re-laparotomy to close the intestinal fistula.

Post-surgery mortality amounted to 2.4%.

In our study, the five-year survival for RPTs was 41.3% after radical surgery, and 9.6% after non-radical surgery.

Relapses of inorganic tumours after radical surgery were detected within five years in 60.8% of cases, of them, in 26.3% of patients with benign neoplasms and 73.7% of patients with malignant tumours. At that, in most cases (52%), the tumour relapses occurred within 18 months after surgery.

Conclusion. There are not standard methods of surgical interventions for non-organic RPTs. The provided data evidences that the cases of locally advanced tumour process are more often in clinical practice.

Any intervention, especially, for locally advanced tumours, is associated with possible complications. A surgical team performing such operation shall be equally experienced in doing abdominal surgery, retroperitoneal surgery, as well as vascular surgery. Such interventions require a highly professional intensive cure and anaesthesia service and adequate infrastructure.

References

1. Navruzov S.N, Dzhuraev M.D, Yusupbekov A.A. Khirurgicheskaya taktika pri neorgannykh zabryushinnykh opukholyakh s prorastaniyem v tolstuyu kishku [Surgical tactics for non-organic retroperitoneal tumors with germination in the large intestine] // Materialy pervogo s'ezda koloproktologov SNG [Proceedings of the 1st Congress of Coloproctologists of the CIS]. - Tashkent, 22-23 October 2009. - P. 218-219.

2. Ignatova E.I. Videolaparoskopiya s primeneniyem intraoperatsionnogo ul'trazvukovogo issledovaniya v diagnostike opukholevykh zabolevaniy bryushnoy polosti i zabryushinnogo prostranstva: avtoref. ... kand.med.nauk. [Videolaparoscopy with the use of intraoperative ultrasound in the diagnosis of tumorous diseases of the abdominal cavity and retroperitoneal space: the author's abstract. ... cand. of medicine]. - M., 2001. – P.27.

3. Klimenkov A.A., Gubina G.I. Neorgannye zabryushinnye opuxoli: osnovnye principy diagnostiki i xirurgicheskoj taktiki [Inorganic retroperitoneal tumors: the basic principles of diagnosis and surgical tactics] // prakticheskaya onkologiya [Practical oncology]. – v. 5, №4. – 2004. – P. 285-290.

4. Navruzov S.N., Dzhuraev M.D., Yusupbekov A.A. Xirurgicheskoe lechenie pervichnyx neorgannyx zabryushinnyx opuxolej [Surgical treatment of primary non-organic retroperitoneal tumors] // ros. onkol. zhurn. [Russian Cancer Journal]. – 2006. – №2. – P. 38-41.

5. Stilidi I.S., Gubina G.I., Nered S.N. Neposredstvennye rezultaty xirurgicheskogo lecheniya neorgannyx zabryushinnyx opuxolej [Direct results of surgical treatment of inorganic retroperitoneal tumors] // ros. onkol. zhurn. [Russian Cancer Journal]. – 2007. – №1. – P. 25-29.

6. Chissov V.I., Vashakmadze L.A., Butenko A.A. // ros. onkol. zhurn. [Russian Cancer Journal]. – 2011. – №3. – P. 4-10.

7. Stauffer J.A., Fakhre G. P., Dougherty M.K. et al. Pancreatic and multiorgan resection with inferior vena cava reconstruction for retroperitoneal leiomyosarcoma // World J Surgery. Oncol. - 2009. - Vol. 6, No. 7. - P. 3.

8. Erzen D., Sencar M., Novak J. / J. Surg.Oncol. - 2009. - Vol.91, No. 1. - P.1-9.

9. Morandeira A., Prieto J., Poves I. et al. Giant retroperitoneal sarcoma. Can J Surg. - 2008. - Vol. 51, No. 4. - P. 79-80.

10. Yoshida Y., Inoue K., Ohsaco T. et al. Weekly paclitaxel therapy is curative for patients with retroperitoneal liposarcoma. Gan To Kagaku Ryoho. - 2007. - Vol. 34. - P. 465-467.