UDC: 616-006.6-078-08

O.N. MUKHAMETGALIEV[1]

[1]Kazakh Research Institute of Oncology and Radiology, Almaty, Republic of Kazakhstan

The first experience of applying cell block technique in the Republic of Kazakhstan

Method of morphological diagnosis of tumours is helpful in complex cases as it combines the minimally invasive fine needle puncture with the histological material posting techniques. The punctate material was placed in citrate plasma. The formed fibrin convolution was fixed in 10% neutral buffered formalin with the following standard histological posting and paraffin embedding. Monoclonal antibodies to thyroglobulin, TTF1, CK7, CK20 were used. The cellular block technique in a combination with immuno-histochemical test proved to be efficient in diagnosing malignant neoplasms.

Keywords: *cell block, immunohistochemistry.*

Introduction. The cell block (CB) technique is relevant in the diagnostics of malignant tumours, where it is possible and preferable to use fine needle punctures (serous cavities, lymph nodes, thyroid and mammary glands, pancreas, liver). The CB method combines the minimally invasive fine needle puncture with the histological technique of wiring the material.

Materials and methods. The punctate material was concentrated by centrifugation, placed in citrate plasma. The formed fibrin convolution was then fixed in 10% neutral buffered formalin, histologically prepared and poured into paraffin. Histological preparations were dyed with haematoxylin-eosin, cytological preparations – with azure-eosin. Monoclonal antibodies to thyroglobulin, TTF1, CK7, CK20 were used.

Results. The method was used in the diagnosis of liver and thyroid gland in patient H. In the punctate of the liver and thyroid gland, similar glandular structures were identified that could be attributed to cholangiocellular carcinoma, colon carcinoma, papillary thyroid carcinoma(high prismatic cells variation) (figure 1).

IHC study was conducted on the cell block (CB) (Figure 2).

Tumour cells were negative to thyroglobulin and TTF1 (Figure 3), so thyroid carcinoma, lung adenocarcinoma were excluded.

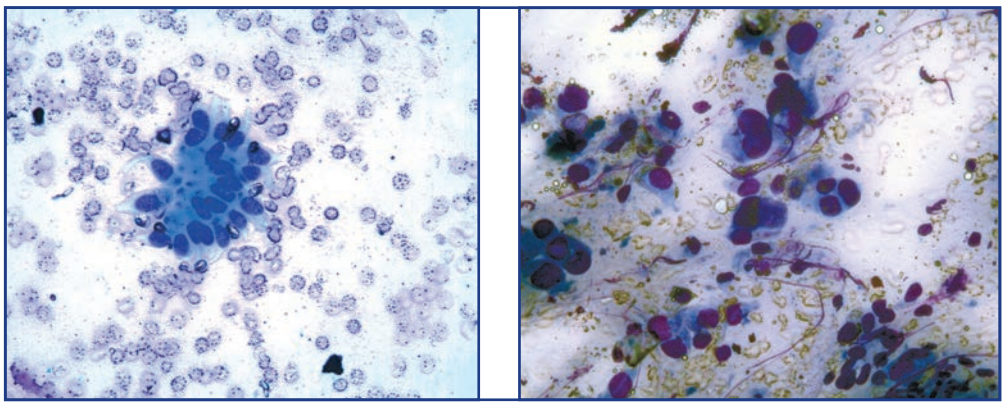

A B

Figure 1 – (A) Complex of atypical cells of liver tumour. (B) – Complex of atypical cells of thyroid gland tumour. (Enl. x 400). AE.

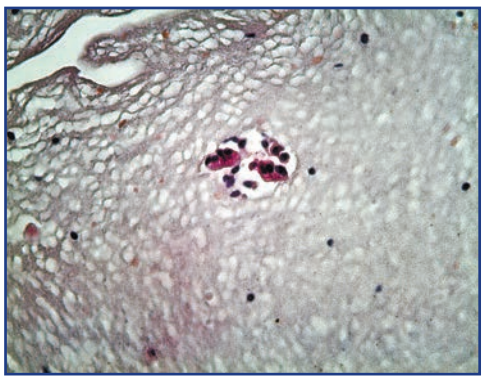

Figure 2 – Complex of atypical cells in thyroid gland tumour. Cell block. (Enl. x400). GE.

CK7 was positive, CK20 was negative (Figure 4) what indicated with a certain degree the tumour of pancreatobiliary tract and stomach.

A B

Figure 3 – (A) Complex of atypical cells in the thyroid gland tumour, negative for thyroglobulin. (B) Complex of atypical cells in the thyroid gland, negative for TTF1. Cell block. (Enl. x400).

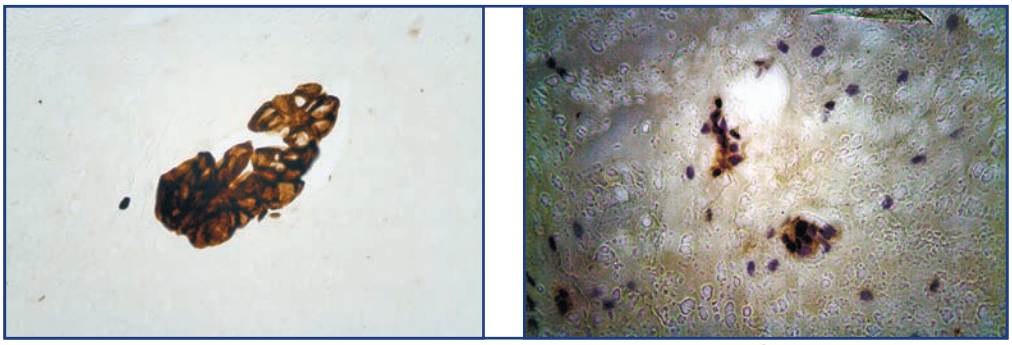

A B

Figure 4 – Complex of atypical cells in the thyroid gland tumour positive for cytokeratin 7 (A) and negative for cytokeratin 20 (B). Cell block. (Enl. x400).

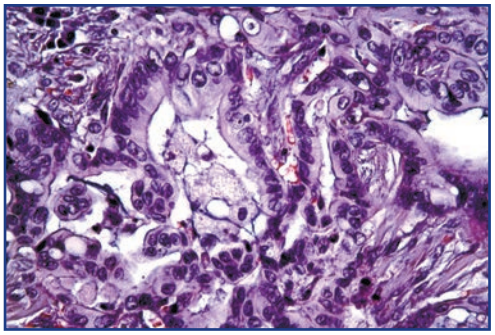

A

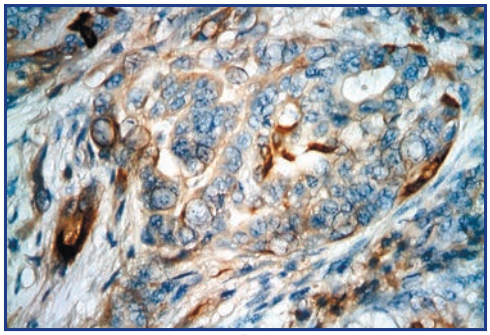

B

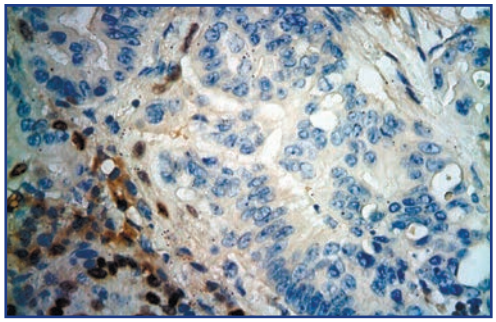

C

Figure 5 - (A) Histological example of the glandular tumor in the thyroid gland. (B) Expression of cytokeratin 20 in individual tumor cells. (C) Lack of expression of TTF1 in tumor cells. (x 400).

Further, hemi-thyroidectomy has revealed in histological preparations a metastasis of highly differentiated adenocarcinoma into the thyroid gland (Figure 5A). In IHC study, CK20 was focal positive on individual cells (Figure 5B), TTF1 was negative on tumour cells and positive on the follicular epithelium (Figure 5C).

Conclusions. Thus, the CB method is effective in diagnosing malignant tumours using a puncture biopsy material in combination with an immunohistochemical study. The obtained results correlated with further histological examinations; however, the level of probability was factor-dependent on the material in the CB substrate. CK20 positive tumour cells did not get into the CB as most of the tumour cells turned to be negative to that antigen (Figure 5B).

References

1. Rowe L.R, Marshall C.J, Bentz J.S. Cell block preparation as an adjunctive diagnostic technique in ThinPrep monolayer preparations: a case report. Diagn Cytopathol. - 2001. - № 24 (2). - P. 142-144.

2. Qiu L, Crapanzano J.P, Sagi A., Vidhum R., et al. Cell block alone as an ideal preparatory method for hemorrhagic thyroid nodule aspirates. - Acta Cytol. - 2008. - №52. - P. 139-144.