

# ENDOSCOPIC REMOVAL OF A RARE LARGE OCCLUSIVE TRACHEAL TUMOR WITH LIMITED TECHNICAL CAPABILITIES

K. BATYRBEKOV<sup>1</sup>, A. GALIAKBAROVA<sup>1</sup>, A. UALIKHANOV<sup>1</sup>

<sup>1</sup>"National Research Oncology Center" LLP, Astana, the Republic of Kazakhstan

## ABSTRACT

**Relevance:** Tracheal tumors often do not cause symptoms until they grow to a size that causes significant airway obstruction, which is the reason for the delay in diagnosis. Diagnosis may also be delayed due to non-specific symptoms, such as cough, wheezing, and shortness of breath, which can occur in other conditions such as asthma and chronic obstructive pulmonary disease. The symptoms that appear may vary depending on the type and location of the tumor. The literature does not sufficiently cover the experience of treating large occlusive tracheal tumors using segmental tracheal resection, endoscopic treatment, or radiation therapy. In scientific literature, the number of published studies with long-term results of endoscopic treatment or radiation therapy of such occlusive tracheal tumors is limited, and this problem requires further study. This article describes the first recorded case of endoscopic removal of a large occlusive tracheal tumor.

**The study aimed to** show the possibility and effectiveness of endoscopic treatment using a minimum set of endoscopic equipment.

**Methods:** This article presents a case of successful minimally invasive endoscopic treatment of a large occlusive tracheal tumor.

**Results:** A large obstructing tumor of the trachea that almost completely blocked the trachea lumen was removed in one block by endoscopic loop resection.

**Conclusion:** The presented clinical case describes the experience of successful endoscopic removal of a rare occlusive tumor of the trachea, which caused shortness of breath at rest and during exercise. For the first time in Kazakhstan, based on the National Scientific Cancer Center, we performed a unique minimally invasive operation to remove a tracheal tumor, while other clinics offered thoracotomic surgical resection methods.

**Keywords:** tracheal tumor, tracheal obstruction, endoscopic treatment, occlusive tumor, schwannoma.

**Introduction:** The trachea connects the larynx to the two main bronchi that supply air to the lungs. Tumors of the trachea can either arise from itself, known as primary tracheal tumors or occur due to direct invasion from nearby structures. Primary tracheal tumors can either be malignant or benign. Malignant primary tracheal tumors, including squamous cell carcinomas and adenoid cystic carcinomas, are more common. Benign primary tracheal tumors include endobronchial hamartomas and squamous cell papillomas [1, 2].

Tracheal tumors often do not produce symptoms until they have grown to a size to cause significant airway obstruction. Therefore, there is a common delay in clinical presentation and diagnosis. Diagnosis may also be delayed due to the presentation of non-specific symptoms such as cough, wheeze, and shortness of breath that can occur in other conditions, such as asthma and chronic obstructive pulmonary disease [3]. When symptoms do appear, they may vary depending on the tumor type and anatomical location. Primary tracheal tumors other than adenoid cystic or squamous cell carcinoma are uncommon and have a heterogeneous histologic appearance. The experience regarding their treatment and long-term outcome is limited, and alternatives to segmental tracheal resection, including endoscopic treatment or radiation, continue to be explored [4].

Overall survival in rare respiratory tract tumors depends on many factors, including the malignant potential of the tumor, concomitant diseases of the patient, localization, and risks associated with the treatment method. Benign tumors are usually localized and can be reduced without or with minimal risk of recurrence. Surgical resection is usually associated with a very low recurrence of benign tumors. Endoscopic removal is associated with varying degrees of recurrence, but

repeated removal is usually possible. Success in endoscopic removal of tracheal neoplasms depends on the tumor size, the patient's condition, and the quality of surgical procedure and anesthetic management.

Unfortunately, endoscopic removal of large benign tumors of the trachea in Kazakhstan is not performed due to insufficient experience of endoscopists and a lack of necessary endoscopic consumables. For that reason, thoracic surgeons often remove such neoplasms via open access. New endoscopic instruments allow for the safe removal of such large formations. However, not all such instruments are available in our country. This article describes the first successful endoscopic removal of a large occlusive tracheal tumor using a minimal selection of endoscopic instruments.

**The study aimed to** show the possibility and effectiveness of endoscopic treatment even with minimal equipment.

**Materials and Methods:** The article describes a successful minimally invasive endoscopic treatment of a large occlusive tracheal tumor.

**Information about the patient:** The patient, a 34-year-old man, was hospitalized in early August 2020 at the National Cancer Research Center for examination and surgical treatment of a tumor in the upper third of the trachea. According to the patient, he had been ill for a month when he first experienced a lack of air.

**Clinical data:** The patient's condition at admission was relatively satisfactory. Clinical manifestations of decompensation of the functions of vital organs and systems were not noted.

**Diagnostics:** Laboratory parameters are within acceptable values. Electrocardiography without acute coronary pathology, conduction, and rhythm disorders.

At the outpatient stage (August 2020), a bronchoscopy revealed a tumor of the upper third of the trachea, completely obstructing the tracheal lumen, causing the patient to have shortness of breath both during physical exertion and at rest.

The chest CT (August 2020) conducted in the National Research Oncology Center (Astana, Kazakhstan) revealed a tumor 2.4x2.3 cm in size, with a leg of 13 mm and a density of

up to 40 U (Figure 1). Next, the patient underwent a video bronchoscopy under additional oxygenation through a nasal catheter. Bronchoscopy revealed a volumetric tumor of the upper third of the trachea, almost completely obstructing its lumen, dense consistency, and pink surface.

Based on clinical data, anamnesis, and tumor localization, the patient was diagnosed with a benign tracheal tumor.

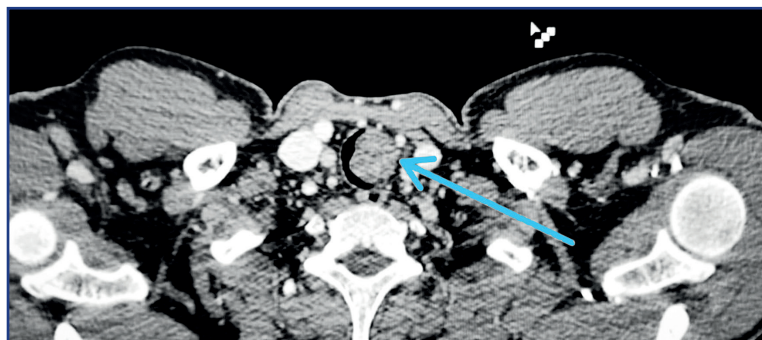


Figure 1 – CT image of the tracheal tumor

**Treatment:** Endoscopic loop resection with subsequent morphological verification was administered due to increased shortness of breath at rest. The first stage included endoscopic intubation with an 8.0 tube. Bronchoscopy of the upper third of the trachea revealed an oval tumor with exophytic growth, 3.5x2.5 cm in size, occupying almost the entire lumen of the trachea, pink in color, dense in palpation, on a thick leg. Next, the tumor was removed using a diathermic loop in the ForceCoag-2 90 Wt mode. The bed was well-main-

tained after coagulation, without signs of wall damage. The patient was extubated with simultaneous tumor extraction from the tracheal lumen. Then the patient was re-intubated under endoscopic control using a bronchoscope and transferred to the recovery room, where he was extubated after 15 minutes and transferred to the clinical department. The patient's anesthetic benefit consisted of deep sedation with propofol 600 mg, short-term muscle relaxation, and oxygen support (Figure 2).

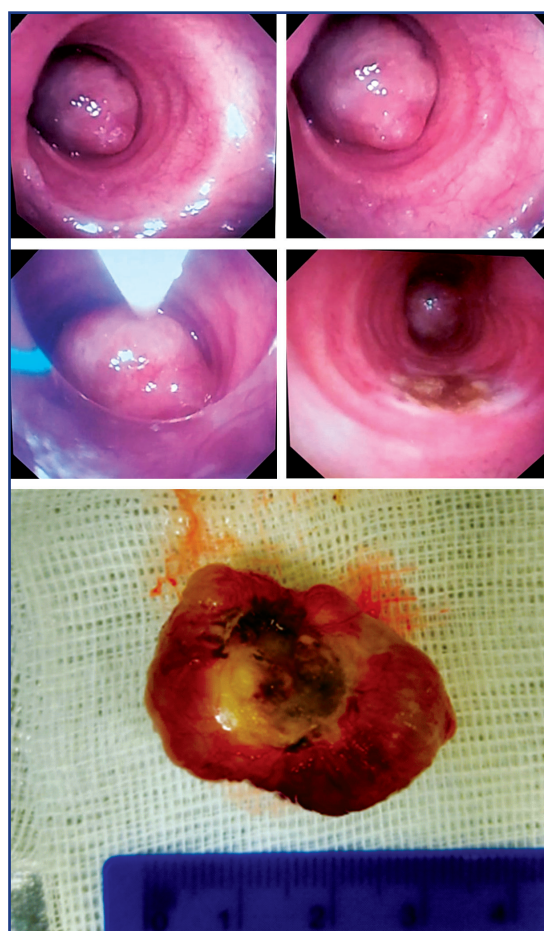

Figure 2 – Images of the tracheal tumor

**Results:** In the first hours after the operation, the patient did not complain of shortness of breath; breathing did not suffer; his quality of life improved. Morphologically, the removed tumor was a tracheal schwannoma (Figure 3). The patient was discharged in satisfactory condition on Day 3 after endoscopic resection.

The presented case is the first successful experience of endoscopic removal of a large occlusive primary tumor recorded in Kazakhstan. Endoscopic neoplasm removal improved the quality of life immediately after surgery, and the postoperative period was short.

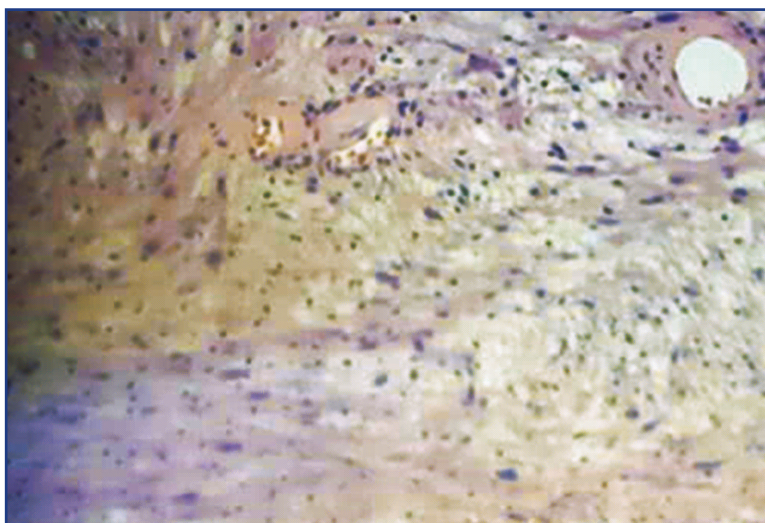


Figure 3 – Photo of the tracheal tumor micro preparation

**Timeline:**

The timeline of this clinical case is presented in table 1.

**Table 1 – Timeline of a clinical case of endoscopic treatment of a benign tracheal tumor**

First visit to a doctor	July 2020
Tumor detection	August 7, 2020
Tumor growth over time	August 12, 2020
Admission to the hospital	August 13, 2020
Endoscopic treatment	August 14, 2020
Discharge from the hospital	August 16, 2020

**Discussion:** Endoscopic methods develop rapidly and gradually replace traditional thoracic and abdominal surgery methods. Endoscopic treatment can be radical in removing benign and borderline tumors; in malignant tumors, it can be palliative for recanalizing the lumen of hollow organs, stenting, and prosthetics. A wider introduction of endoscopic methods requires a retrospective study of long-term endoscopic treatment outcomes, assessing treatment radicality and effectiveness and the presence and tactics for complications. Successful endoscopic resection of such large tracheal tumors requires an experienced team of an endoscopist and an anesthesiologist. This surgery requires a rigid bronchoscope and an argon plasma coagulator. Since this was our first experience removing such a tumor and we did not possess a rigid bronchoscope, we decided to perform a loop resection of the tumor and its subsequent extraction from the trachea with simultaneous patient extubation.

**Conclusion:** Given the insidious progression of benign tracheal tumors, their diagnostics remain an intricate task. Despite low differentiation of cases of airway obstruction, they may turn out to be dangerous due to

almost complete tracheal obstruction, as in the case described. The tumors can involve several important paratracheal structures, making resection and reconstruction more challenging. Extensive damages also complicate operational planning. The choice between endobronchial removal or surgical resection still depends on the patient and tumor characteristics and the experience of the endoscopist and anesthetic team [5]. Small, fully endoluminal tumors with a limited spread in the tracheobronchial tree and a low risk of recurrence, as well as poor candidates for surgery, can benefit from endobronchial removal and avoid the pain of surgical removal and reconstruction.

**References:**

1. Saoud M., Patil M., Dhillon S.S., Pokharel S., Picone A., Hennon M., Yendamuri S., Harris K. Rare airway tumors: an update on current diagnostic and management strategies // *J. Thorac. Dis.* – 2016. – Vol. 8(8). – P. 1922-1934. <https://doi.org/10.21037%2Fjtd.2016.07.40>
2. Hamouri S., Novotny N.M. Primary tracheal schwannoma a review of a rare entity: current understanding of management and follow-up // *J. Cardiothorac. Surg.* – 2017. – Vol. 12. – Art. no. 105. <https://cardiothoracicsurgery.biomedcentral.com/articles/10.1186/s13019-017-0677-2>
3. Lin M., Song L., Qin S., Li D., Hou G., Li X. Plexiform fibromyxoma: case report and literature review // *Medicine.* – Vol. 100(36). – P. e27164. <https://dx.doi.org/10.1097/MD.00000000000027164>
4. Gaisert H.A., Grillo H.C., Shadmehr M.B., Wright C.D., Gokhale M., Wain J.C., Mathisen D.J. Uncommon primary tracheal tumors // *Ann. Thor. Surg.* – 2006. – Vol. 82 (1). – P. 268-273. <https://doi.org/10.1016/j.athoracsur.2006.01.065>
5. Мухамадиев Б.Т. Анестезиологическое обеспечение эндотрахеобронхиальных операций при опухолевом поражении центральных бронхов и трахеи // *Онкология и радиология Казахстана.* – 2012. – № 24-25 (2-3). – С. 23-25 [Muxamadiev B.T. Anesteziologicheskoe obespechenie e'ndotraxeobronxial'nyx operacij pri opuxolevom porazhenii central'nyx bronxov i traxei // *Onkologiya i radiologiya Kazaxstana.* – 2012. – № 24-25 (2-3). – S. 23-25 (in Russ.)]. <http://oncojournal.kz/anesteziologicheskoe-obe-spechenie-ehnd/>

## АНДАТПА

## ТЕХНИКАЛЫҚ МҮМКІНДІКТЕРІ ШЕКТЕУЛІ ТРАХЕЯНЫҢ СИРЕК КЕЗДЕСЕТІН ІРІ ОККЛЮЗИЯЛЫҚ ІСІГІН ЭНДОСКОПИЯЛЫҚ АЛЫП ТАСТАУ

К. Батырбеков<sup>1</sup>, А. Галиакбарова<sup>1</sup>, А. Уәлиханов<sup>1</sup>

«Ұлттық ғылыми онкологиялық орталық» ЖШС, Астана, Қазақстан Республикасы

**Өзектілігі:** трахея ісіктері көбінесе тыныс алу жолдарының айтарлықтай кедергісін тудыратын мөлшерге дейін симптомдар тудырмайды, бұл диагноздың кешігуіне себеп болады. Демікпе және созылмалы обструктивті өкпе ауруы сияқты басқа жағдайларда пайда болуы мүмкін жөтел, ысқырық және ентігу сияқты спецификалық емес белгілердің көрінуіне байланысты диагнозды кейінге қалдыруға болады. Пайда болған белгілер ісіктің түріне және орналасуына байланысты өзгеруі мүмкін. Трахеяның сегменттік резекциясын, эндоскопиялық лечение немесе сәулелік терапияны қоса алғанда, үлкен окклюзивті трахея ісігін емдеу тәжірибесі әдебиетте жеткілікті түрде қамтылмаған. Әлемдік ғылыми әдебиеттерде мұндай окклюзиялық трахея ісіктерін эндоскопиялық емдеудің немесе сәулелік терапияның ұзақ мерзімді нәтижелері бар жарияланған зерттеулердің саны шектеулі және бұл мәселе қосымша зерттеуді қажет етеді. Бұл мақалада трахеяның үлкен окклюзиялық ісігін эндоскопиялық алып тастаудың алғашқы тіркелген жағдайы сипатталған.

**Зерттеудің мақсаты** – эндоскопиялық жабдықтың минималды жиынтығын пайдалану кезінде эндоскопиялық емдеудің мүмкіндігі мен тиімділігін көрсету.

**Әдістері:** Бұл мақалада трахеяның үлкен окклюзиялық ісігін сәтті минималды инвазивті эндоскопиялық емдеу жағдайы келтірілген.

**Нәтижелері:** эндоскопиялық шпательдік резекция нәтижесінде трахеяның люменін толығымен жабатын трахеяның үлкен обтура-торлық ісігі бір блоком жойылды.

**Қорытынды:** ұсынылған клиникалық жағдай тыныштықта және жаттығу кезінде ентігуді тудырған сирек кездесетін окклюзиялық трахея ісігін сәтті эндоскопиялық алып тастау тәжірибесін сипаттайды. Қазақстанда алғаш рет Ұлттық ғылыми онкологиялық орталық базасында біз трахея ісігін жою бойынша бірегей миниинвазивті операция жасадық, ал басқа клиникаларда резекцияның торакотомиялық хирургиялық әдістері ұсынылды.

**Түйінді сөздер:** трахея ісігі, трахеяның бітелуі, эндоскопиялық емдеу, окклюзиялық ісік, шваннома.

## АННОТАЦИЯ

## ЭНДОСКОПИЧЕСКОЕ УДАЛЕНИЕ РЕДКОЙ КРУПНОЙ ОККЛЮЗИОННОЙ ОПУХОЛИ ТРАХЕИ С ОГРАНИЧЕННЫМИ ТЕХНИЧЕСКИМИ ВОЗМОЖНОСТЯМИ

К. Батырбеков<sup>1</sup>, А. Галиакбарова<sup>1</sup>, А. Уәлиханов<sup>1</sup>

ТОО «Национальный Научный Онкологический Центр», Астана, Республика Казахстан

**Актуальность:** Опухоли трахеи часто не вызывают симптомов до тех пор, пока они не вырастут до размеров, вызывающих значительную обструкцию дыхательных путей, что является причиной задержки в постановке диагноза. Диагностика также может быть отсрочена из-за проявления неспецифических симптомов, таких как кашель, свистящее дыхание и одышка, которые могут возникать при таких состояниях, как астма и хроническая обструктивная болезнь легких. Появляющиеся симптомы могут варьировать в зависимости от типа и локализации опухоли. Опыт в отношении лечения крупной окклюзионной опухоли трахеи, включая сегментарную резекцию трахеи, эндоскопическое лечение или лучевую терапию, недостаточно освещен в литературе. В мировой научной литературе количество опубликованных исследований с отдаленными результатами эндоскопического лечения или лучевой терапии таких окклюзионных опухолей трахеи ограничено, и эта проблема требует дальнейшего изучения. В этой статье описывается первый зарегистрированный случай эндоскопического удаления большой окклюзионной опухоли трахеи.

**Цель исследования** – показать возможность и эффективность эндоскопического лечения при использовании минимального набора эндоскопического оборудования.

**Методы:** В данной статье представлен случай успешного малоинвазивного эндоскопического лечения крупной окклюзионной опухоли трахеи.

**Результаты:** В результате эндоскопической петлевой резекции одним блоком удалена крупная обтурирующая опухоль трахеи, практически полностью перекрывавшая просвет трахеи.

**Заключение:** Представленный клинический случай описывает опыт успешного эндоскопического удаления редкой окклюзионной опухоли трахеи, которая вызывала одышку в покое и при физической нагрузке. Впервые в Казахстане на базе Национального научного онкологического центра нами была проведена уникальная малоинвазивная операция по удалению опухоли трахеи, в то время как в других клиниках предлагались торакотомические хирургические методы резекции.

**Ключевые слова:** опухоль трахеи, обструкция трахеи, эндоскопическое лечение, окклюзионная опухоль, шваннома.

**Transparency of the study:** Authors take full responsibility for the content of this manuscript.

**Conflict of interest:** Authors declare no conflict of interest.

**Financing:** Authors declare no financing of the study.

**Authors' input:** contribution to the study concept – Bатырбеков К., Галиакбарова А., Уәлиханов А.; study design – Bатырбеков К., Уәлиханов А.; execution of the study – Bатырбеков К., Галиакбарова А.; interpretation of the study – Bатырбеков К.; preparation of the manuscript – Bатырбеков К.

**Authors' data:**

**Bатырбеков Канат (corresponding author)** – Ph.D., Chief of the Expert Endoscopy and Interventional Radiology Department, National Research Oncology Center, Astana, Kazakhstan, tel. +77074744980, e-mail: dr.kanat77@gmail.com, ORCID ID: 0000-0003-4837-0775;  
**Галиакбарова Айнур** – endoscopist of the Expert Endoscopy and Interventional Radiology Department, National Research Oncology Center, Astana, Kazakhstan, tel. +77072676316, e-mail: ainura-endo@mail.ru, ORCID ID: 0000-0002-9588-0025;  
**Уәлиханов Асет** – endoscopist of the Expert Endoscopy and Interventional Radiology Department, National Research Oncology Center, Astana, Kazakhstan, tel. +77055113069, e-mail: assetmed@mail.ru, ORCID ID: 0000-0001-6865-3006.

**Address for correspondence:** Bатырбеков Канат, National Research Oncology Center, Kerey Zhanibek Khandar St. 3, Astana 020000, the Republic of Kazakhstan.