

# ENDOSCOPIC TREATMENT OF BARRETT'S ESOPHAGUS IN KAZAKHSTAN

**K. BATYRBEKOV<sup>1</sup>, A. GALIAKBAROVA<sup>1</sup>**

<sup>1</sup>Center of expert endoscopy and interventional radiology of the National Research Oncology Center, Astana, the Republic of Kazakhstan

## ABSTRACT

**Relevance:** Barrett's esophagus (BE) is a special disease characterized by metaplasia of the flat epithelium of the esophagus.

The main danger of esophageal epithelial metaplasia is the high probability of developing a malignant neoplasm at the site of the lesion – esophageal adenocarcinoma or cancer of the cardioesophageal zone.

**The study aimed to** evaluate the clinical effectiveness of new BE endoscopic treatment methods for their subsequent implementation in wide practice throughout the Republic of Kazakhstan.

**Methods:** This article presents cases of clinical use of argon plasma coagulation of dysplasia lesions less than 2.0 cm in two patients with Barrett's esophagus and the use of loop resection of dysplasia lesions more than 2.0 cm in three patients with Barrett's esophagus.

**Results:** All the presented cases have shown the effectiveness of applied treatment. Control morphological examination showed no signs of BE in the epithelium.

**Conclusion:** The presented article describes the results of the introduction of endoscopic BE treatment methods in our clinic and is available for wide implementation throughout Kazakhstan. A widespread introduction of endoscopic treatment of precancerous pathology will reduce the incidence of esophageal cancer in the Kazakhstani population.

**Keywords:** Barrett's esophagus (BE), metaplasia, endoscopy, esophageal neoplasms, gastroesophageal reflux.

**Introduction:** Barrett's esophagus (BE) is a special condition characterized by metaplasia of the esophageal squamous epithelium. This pattern is observed during the long course of gastroesophageal reflux disease and is one of its most serious complications.

The incidence of BE is about 10% of all identified cases of gastroesophageal reflux (among treated patients); in the general population, the disease occurs in about one in 100 adults. According to statistics, in a year, cancer degeneration into esophageal adenocarcinoma occurs in 6-7 patients out of 1000 suffering from Barrett's esophageal disease [1]. Unfortunately, there is no data on BE incidence and detectability in Kazakhstan. This article describes the first successful experience of administering new endoscopic treatment in patients with Barrett's esophagus in Kazakhstan. For further scientific research, we propose monitoring such patients to identify the effectiveness of treatment, the radicality of treatment when using endoscopic methods of ablation of Barrett's esophagus, the presence of relapse, complications, and other indicators.

The main danger of esophageal epithelial metaplasia is the high probability of developing a malignant neoplasm at the site of the lesion – esophageal adenocarcinoma or cancer of the cardioesophageal zone.

The only reliable method of diagnosing Barrett's metaplasia is detecting a special type of goblet cells of the intestinal epithelium in biopsy material taken from the affected area of the esophageal mucosa. These cells indicate the transformation that has occurred with the epithelium of the esophagus, which is dangerous for further degeneration into cancer.

Endoscopy can help establish a preliminary diagnosis since Barrett's metaplasia has a characteristic visual pic-

ture: foci of metaplasia against the background of light pink normal esophageal epithelium look like "flames." This sign occurs due to atrophy of the mucous membrane and the transmission of small blood vessels passing longitudinally through its surface layer [2].

Endoscopic treatment methods are used with severe dysplasia or early esophageal cancer. The most common methods of BE endoscopic treatment are "aspiration and resection": using a distal cap and ligature, as well as argon plasma coagulation (APC). In the first case, the pathological site is aspirated into the cavity of a plastic cap, which is pre-installed at the distal end of the endoscope, and resection is performed using an electrosurgical loop previously opened inside the cap. Before resection, a saline solution is injected into the submucosal layer under the base of the pathological site to prevent perforation. In the second case, the pathological site is coagulated by an argon plasma coagulator. Both methods are equally effective and safe for the ablation of BE [3, 4].

**The study aimed to** evaluate the clinical effectiveness of new BE endoscopic treatment methods for their subsequent implementation in wide practice throughout the Republic of Kazakhstan.

**Materials and methods:** In 2020-2022, the BE endoscopic resection was performed in 3 patients and the endoscopic APC – in 2 patients with BE. All patients provided informed consent before the endoscopic intervention. APC was used with BE up to 2.0 cm in size. Endoscopic loop resection was used in BE with a segment size > 2 cm [5, 6].

Endoscopic mucosal resection of sections of the metaplastic esophageal mucosa with dysplasia sites was performed in an endoscopic operating room under intubation anesthesia using a 6-charge captivator (Boston

Scientific, USA) for a semicircular endoscopic mucosal resection (EMR). All resected areas were extracted and sent for morphology. Endoscopic treatment was accompanied by antisecretory therapy using proton pump inhibitors for effective and rapid healing of mucosal defects and creating conditions for the appearance of multilayer

flat epithelium of the esophagus in these areas. The control examination was carried out after 1.5 months with a mandatory sampling of biopsy material from the esophagus; subsequent morphological examination confirmed that the new epithelium had no signs of mucosal metaplasia (Figure 1).

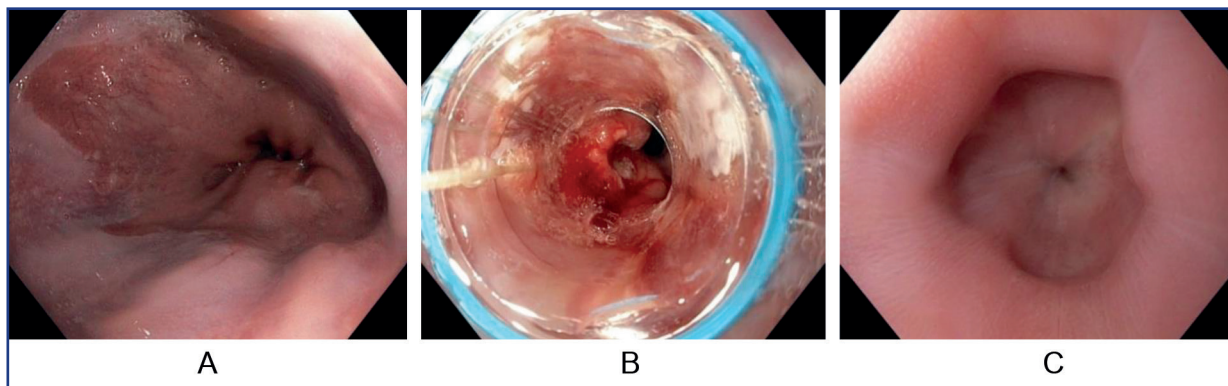


Figure 1 – Endoscopic Barrett’s esophagus loop resection using EMR Captivator: A – before resection, B – during resection, C – one month after resection

APC was performed using an “Olympus ESG 300/APU300” (Japan) high-frequency generator and two “Olympus” probes of 2.3 and 3.2 mm in diameter. The argon feed rate was from 0.5 to 1 l/min; the power ranged from 20 to 50 W. The choice of the coagulation program in each case was carried out individually, taking into account the localization and nature of the pathological focus and

the visible effect of coagulation. During the APC, the necessary precautions were observed: coagulation was carried out only under visual control, the probe was not allowed to come into contact with tissues, an aspirator was used to prevent overgrowth of the hollow organ, and the insufflation of the esophageal lumen was carried out with a CO<sub>2</sub> insufflator (Figure 2).

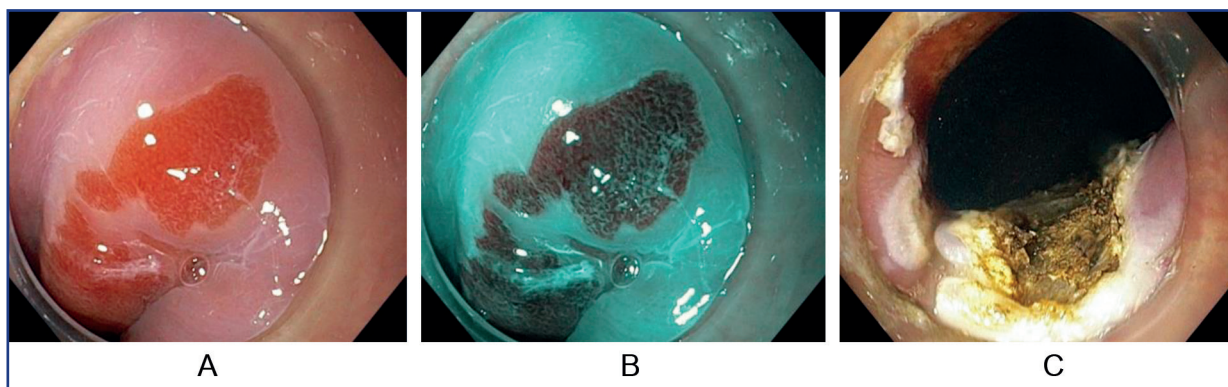


Figure 2 – Barrett’s esophagus (BE) endoscopic argon plasma coagulation (APC): A – BE image, B – BE with narrow band imaging; C – BE after APC

APC method was used for BE with epithelial dysplasia, BE with segment size < 2 cm, and pathomorphologically confirmed diagnosis. APC in patients with BE was started from the edges of the metaplastic segment to clearly distinguish the pathological focus for ablation. After APC, the patient received omeprazole 20 mg 2 times a day for four weeks. All patients underwent a mandatory biopsy (from 2 to 4 fragments, depending on the segment size) a month after APC. The biopsy sample was taken from the BE segment previously subjected to APC.

**Results:** No complications after APC was registered. One patient developed a circular stricture after loop resection in the postoperative period, successfully resolved after

four gullet bougienages. Deep sedation allows the operator to work in a calm environment without fear of uncontrolled movements on the part of the patient. This is especially important when working in the esophageal-gastric junction zone when a conscious patient’s vomiting actions do not allow for rapid, targeted coagulation and increase the risk of iatrogenic damage. All patients underwent one-stage intervention; the second stage of ablation or loop resection was not required. The pathomorphological examination of the material taken at the control examination showed no metaplastic and/or dysplastic changes in the mucous membrane of the lower third of the esophagus. Thus, a single APC was radical in all patients with a BE size

of <1 cm and loop resection in all patients with a BE size of more than 2 cm.

**Discussion:** In Kazakhstan, endoscopic treatment of patients with dysplasia in Barrett's esophagus has just started at the National Research Oncology Center. It will take a long time to monitor a large group of patients for ten years after therapy to publish far-reaching results. Endoscopic treatment of dysplastic BE is known to be successful in 90% of patients [6]. What is less well understood is how long this benefit lasts and whether it contributes to a significant reduction in cancer progression. Further research requires a larger number of patients and the division of patients into groups with low and severe dysplasia. Long-term monitoring of patients for recurrence and progression of dysplastic changes is also required. And, of course, a national registry of patients with Barrett's esophagus is required for further epidemiological surveillance.

**Conclusions:** Thus, the tactics of managing patients with BE in the presence of dysplasia involve conducting a thorough endoscopic examination of the metaplasia area in a specialized expert center using modern endoscopic techniques to identify visible pathological areas. In the absence of visible pathological areas in the metaplasia segment, BE eradication using modern ablation methods is required. A detected pathological site should be removed by endoscopic resection followed by histo-

logical evaluation. A severe dysplasia or intra-mucosal cancer in a remote area requires eliminating the remaining segment of BE metaplasia using endoscopic ablation methods. This experience of BE endoscopic treatment at the National Research Oncology Center can be put into wide practice in all oncology clinics of the Republic of Kazakhstan.

#### References:

- Standards of Practice Committee, Wani S., Qumsey B., Sultan S., Agrawal D., Chandrasekhara V., Harnke B., Kothari S., McCarter M., Shaukat A., Wanf A., Yang J., Dewitt J. Endoscopic eradication therapy for patients with Barrett's esophagus-associated dysplasia and intramucosal cancer//Gastrointest. Endosc. – 2018. – Vol. 87(4). – P. 907-931.E9.https://doi.org/10.1016/j.gie.2017.10.011
- Cholapranee A., Trindade A.J. Challenges in Endoscopic Therapy of Dysplastic Barrett's Esophagus // Curr. Treat. Opt. Gastroenterol. – 2019. – Vol. 17. – P. 32-47.https://doi.org/10.1007/s11938-019-00215-8
- Ishihara R., Arima M., Iizuka T. Endoscopic submucosal dissection/endoscopic mucosal resection guidelines for esophageal cancer // Digest. Endosc. – 2020. – Vol. 32. – P. 452-493.https://doi.org/10.1111/den.13654
- Sami S.S., Ravindran A., Kahn A. Timeline and location of recurrence following successful ablation in Barrett's oesophagus: An international multicentre study // Gut. – 2019. – Vol. 68. – P. 1379-1385. https://doi.org/10.1136/gutjnl-2018-317513
- Kolb J.M., Wani S. Barrett's esophagus: Current standards in advanced imaging // Transl. Gastroenterol. Hepatol. – 2021. – Vol. 6. – P. 14. https://doi.org/10.21037/tgh.2020.02.10
- Wronska E., Polkowski M., Orłowska J. Argon plasma coagulation for Barrett's esophagus with low-grade dysplasia: A randomized trial with long-term follow-up on the impact of power setting and proton pump inhibitor dose // Endoscopy. – 2021. – Vol. 53. – P. 123-132.https://doi.org/10.1055/a-1203-5930

## АНДАТПА

### ҚАЗАҚСТАНДА БАРРЕТТ ӨҢЕШІН ЭНДОСКОПИЯЛЫҚ ЕМДЕУ

К. Батырбеков<sup>1</sup>, А. Галиакбарова<sup>1</sup>

<sup>1</sup>Сараптамалық эндоскопия және интервенциялық радиология орталығы, Ұлттық ғылыми онкологиялық орталық, Астана, Қазақстан Республикасы

**Өзектілігі:** Барреттің өңеші (БӨ) – бұл өңештің жалпақ эпителий метоплазиясымен сипатталатын ерекше ауру. Өңеш эпителийінің метоплазиясының негізгі қауіптілігі зақымдану орнында қатерлі ісіктің даму ықтималдығы жоғары – өңеш аденокарциномасы немесе кардиоэзофагеальды аймақтың қатерлі ісігі.

**Зерттеудің мақсаты** кейіннен Қазақстан Республикасы бойынша кең тәжірибеге енгізу үшін БӨ емдеудің жаңа эндоскопиялық әдістерінің клиникалық тиімділігін бағалау болды.

**Әдістері:** Бұл мақалада Баррет өңеші бар екі пациентте 2,0 см-ден аз дисплазия ошақтарының аргоноплазмалық коагуляциясын клиникалық қолдану және Баррет өңеші бар үш пациентте 2,0 см-ден астам дисплазия ошақтарының циклдік резекциясын қолдану жағдайлары келтірілген.

**Нәтижелер:** барлық ұсынылған жағдайлар қолданылатын емнің тиімділігін көрсетті. Бақылау морфологиялық зерттеуі эпителийде БӨ белгілерін анықтаған жоқ.

**Қорытынды:** ұсынылған мақала біздің клиникада БӨ емдеудің эндоскопиялық әдістерін енгізу нәтижелерін сипаттайды және бүкіл Қазақстан бойынша кеңінен енгізу үшін қолжетімді. Қатерлі ісікке дейінгі патологияны эндоскопиялық емдеуді кеңінен енгізу Қазақстан халқы арасында өңеш обьрымен сырқаттанушылықты азайтуға мүмкіндік береді.

**Түйінді сөздер:** барреттің өңеші, метоплазия, эндоскопия, өңештің ісіктері, газозофагеальды рефлюкс.

## АННОТАЦИЯ

### ЭНДОСКОПИЧЕСКОЕ ЛЕЧЕНИЕ ПИЩЕВОДА БАРРЕТТА В КАЗАХСТАНЕ

К. Батырбеков<sup>1</sup>, А. Галиакбарова<sup>1</sup>

<sup>1</sup>Центр экспертной эндоскопии и интервенционной радиологии, Национальный Научный Онкологический Центр, Астана, Республика Казахстан

**Актуальность:** Пищевод Барретта (ПБ) – это особое заболевание, характеризующееся метоплазией плоского эпителия пищевода. Основной опасностью метоплазии эпителия пищевода является высокая вероятность развития злокачественного новообразования на месте поражения – аденокарциномы пищевода или рака кардиоэзофагеальной зоны.

**Целью исследования** была оценка клинической эффективности новых эндоскопических методов лечения ПБ для их последующего внедрения в широкую практику по всей Республике Казахстан.

**Методы:** В данной статье представлены случаи клинического применения аргоноплазменной коагуляции очагов дисплазии менее 2,0 см у двух пациентов с пищеводом Барретта и применения петлевой резекции очагов дисплазии более 2,0 см у трех пациентов с пищеводом Барретта.

**Результаты:** Все представленные случаи показали эффективность применяемого лечения. Контрольное морфологическое исследование не выявило признаков ПБ в эпителии.

**Заключение:** Представленная статья описывает результаты внедрения эндоскопических методов лечения ПБ в нашей клинике и доступна для широкого внедрения по всему Казахстану. Широкое внедрение эндоскопического лечения предраковой патологии позволит снизить заболеваемость раком пищевода среди населения Казахстана.

**Ключевые слова:** пищевод Барретта, метаплазия, эндоскопия, новообразования пищевода, газозофагеальный рефлюкс.

---

**Transparency of the study:** Authors take full responsibility for the content of this manuscript.

**Conflict of interest:** Authors declare no conflict of interest.

**Financing:** Authors declare no financing of the study.

**Authors' input:** contribution to the study concept – Batyrbekov K., Galiakbarova A.; study design – Batyrbekov K.; execution of the study – Batyrbekov K., Galiakbarova A.; interpretation of the study – Batyrbekov K.; preparation of the manuscript – Batyrbekov K.

**Authors' data:**

**Galiakbarova Ainur** – endoscopist of the Expert Endoscopy and Interventional Radiology Department, National Research Oncology Center, Astana, the Republic of Kazakhstan, tel. +77072676316, e-mail: ainura-endo@mail.ru, ID ORCID: <https://orcid.org/0000-0002-9588-0025>;

**Batyrbekov Kanat (corresponding author)** – Ph.D., Chief of the Expert Endoscopy and Interventional Radiology Department, National Research Oncology Center, Astana, 020000, Kerey Zhanibek Khandar St. 3, the Republic of Kazakhstan, tel. +77074744980, e-mail: email: dr.kanat77@gmail.com, ID ORCID: <https://orcid.org/0000-0003-4837-0775>.