UDC: 616-006.488-089

DOI: 10.52532/2663-4864-2022-2-64-28-32

AN ANALYSIS OF AN INTEGRATED APPROACH TO CAROTID BODY TUMOR SURGICAL TREATMENT AT THE NATIONAL RESEARCH ONCOLOGY CENTER (NUR-SULTAN, KAZAKHSTAN)

***A.K. TULEMISSOV*[1]**

[1]«National Research Oncology Center» LLP, Nur-Sultan, the Republic of Kazakhstan

ABSTRACT

Relevance: *Carotid body tumors (CBT) account for 0.01% of all head and neck tumors. 5-15% of CBTs are malignant. The expansive growth of this tumor and its tight attachment to the carotid arteries pose a risk of damage to the main blood vessels and cranial nerves during surgery, which can lead to life-threatening bleeding. Today, preoperative embolization of CBT feeding vessels (PECBT) is used to minimize blood loss during CBT radical excision.*

The study aimed to *evaluate the results of preoperative preparation of patients with CBT by PECBT; justification of a CBT incidence multicenter study to determine CBT's current status in Kazakhstan.*

Methods: *An anamnesis was collected from all patients, and instrumental diagnostic studies (ultrasound, CTA) were performed. We used the Shamblin (1971) classification of CBT modified by Luna-Ortiz et al. (2006). PECBT was performed to prepare patients for open surgery. CBT excision tactics were selected depending on the classification of the CBT, according to Shamblin.*

Results: *Out of 9 patients with CBT, seven patients complained mainly of a neck tumor; the others mentioned pain and dysphagia. Four patients had a left-side CBT, and the others had a right-side. One tumor was Shamblin type I, five were Shamblin type II, and three were Shamblin type III. Eight patients underwent PECBT, and one was operated on without PECBT. In 8 cases, CBT was surgically incised; one patient did not show up for the second stage of treatment. Arterial reconstruction was required in two cases. First, an average size tumor was 27.4 cm^3. The CBT excision was controlled without significant bleeding thanks to the presence of an embolic agent. Blood loss averaged 750 ml; reinfusion – 243.3 ml.*

Conclusion: *The CBT incidence in Kazakhstan has not been studied yet, so a multicenter study is required. Early ultrasound and CT diagnostics support providing patients with up-to-date, efficient surgical treatment. In addition, PECBT provides favorable conditions for tumor resection without hemodynamically significant blood loss.*

Keywords: *carotid body tumor, chemodectoma, vascular neoplasm, carotid basin, carotid reconstruction, endovascular embolization.*

Introduction: Carotid body tumor, also known as carotid chemodectoma (CC), is the most common head and neck paraganglioma (HNP) [1, 2]. CC originates from paraganglionic cells of the carotid body [1, 3] and accounts for 0.01-0.6% of all head and neck neoplasms [2, 4]. Even though CC is more often a benign tumor, malignant forms of CC occur in 5% of cases [2]. In order to determine the treatment tactics for HNP, it is necessary to make a careful differential diagnosis of HNP from other types of HNP, referred to as non-carotid chemodectoma (non-CC) [5, 6]. A CC is characterized by its hypervascular structure with multiple arteries feeding the tumor. Radical excision of the CC (ECC) is recommended in all patients [5, 6] due to the risk of compression of vital anatomical elements of the neck, such as significant vessels, cranial nerves (CNs), trachea, and esophagus. However, the risk of damage to significant blood vessels and the HNP during surgical intervention remains high, leading to the lightning-fast development of clinically significant bleeding [1]. To date, preoperative embolization of the arteries feeding the CC (PECC) minimizes blood loss during radical tumor removal. However, there are still controversial opinions about the effectiveness of this method [7, 8]. Moreover, the low prevalence of this neoplasm and paucity of epidemiological studies do not allow determining the current status of CC incidence in the Republic of Kazakhstan. Instead, the article presents a series of clinical cases of complex approaches to surgical treatment of patients with CC at the National Research Oncology Center (NROC), Nur-Sultan, Kazakhstan.

The study aimed to evaluate the results of preoperative preparation of patients with CBT by PECBT; justification of a CBT incidence multicenter study to determine CBT's current status in Kazakhstan.

Materials and Methods: Data of 9 patients with CC who received treatment in NSOC from 2014 to 2021 were included in the study. Written informed consent for the publication of clinical data was obtained from patients. The study was conducted by the Declaration of Helsinki and approved by the Local Ethics Committee of NROC.

Diagnostics: Diagnostics were made in two main steps. The first stage was anamnesis collection, in which the patient's primary complaints were established, as well as phys-

ical examination of the patient, including palpation and auscultation of the neck mass. In the second stage, ultrasound Doppler sonography (USDS) and computed tomography angiography (CTA) of the neoplasm were performed. USDS allows determining the localization of the neoplasm in the carotid bifurcation zone and its vascular structure in color duplex mapping mode. Finally, on CTA, the CC is stained with a contrast agent, which enables it to determine its size and spatial relation to the main vessels [2].

Tumor classification

In this study, we applied the classification proposed by Shamblin (1971) and modified by Luna-Ortiz et al. (2006), according to which CC is divided into three types [4]. Shamblin classification is based on radiological data [3]. The division depends on the degree of involvement of the main vessels in the tumor mass and the presence of transmural growth of the neoplasm in the arterial wall (Figure 1).

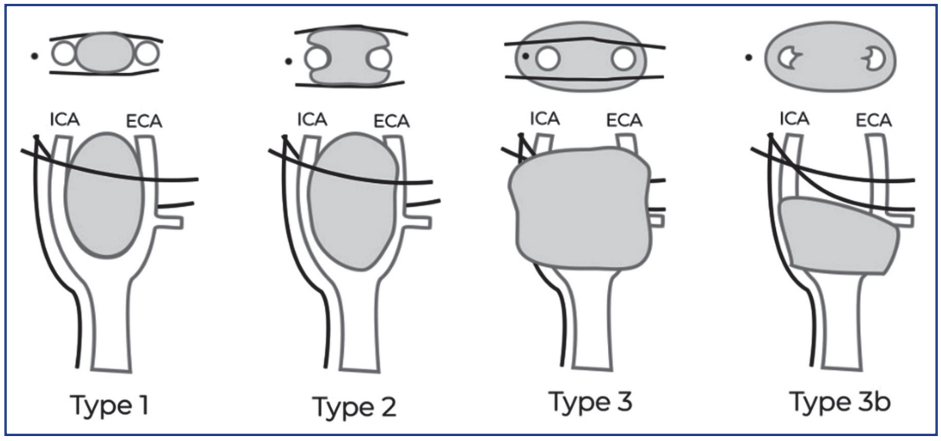

Figure 1 – Carotid chemodectoma classification by Shamblin (1971) as modified by Luna-Ortiz (2006) [4]

Treatment

As part of a comprehensive approach to surgical treatment of patients with CC, we used two stages of treatment. The first stage was PECC to trigger tumor involution and reduce intraoperative bleeding in the second stage.

ECC was performed as the second stage of surgical treatment. Below is a detailed description of both stages.

1) Preoperative embolization

A catheter is inserted into an introductory inserted into the common femoral artery. After passing through the aorta, the catheter is selectively inserted into the lumen of the common carotid artery. A contrast agent injected into the carotid arterial basin evaluates the CC and the arteries feeding it. After systemic administration of an anticoagulant drug, the protective device is placed distally into the internal carotid artery (ICA) to prevent acute cerebral circulation disorder (ACCD). Then, embolization of the CC using microspheres is performed using a microcatheter placed supra selectively into the artery feeding the CC. The procedure's efficacy is assessed by the degree of blood flow reduction in the CC on control images.

2) Carotid body tumor dissection

The surgical intervention is performed under general anesthesia. The patient is placed in the supine position with the neck extended and the head turned in the opposite direction from the intended incision. The incision is made along the medial margin of the sternocleidomastoid muscle from the angle of the mandible to the jugular notch. The main arteries (common, external, and internal carotid arteries) are exposed along the course of the exposure of the CC, over which control is ensured. Gentle separation of the CNs from the tumor is possible by separating them through the pseudo capsule surrounding the neoplasm. If necessary, it is possible to dissect the posterior abdomen of the double-bellied muscle to expose the distal parts of the tumor. When isolating and skeletonizing the external and internal carotid arteries, the proximal position of several nerve trunks should be considered: the hyoid nerve, upper laryngeal nerve, the lower branch of the facial nerve, the laryngeal branch of the vagus nerve, and the lingual pharyngeal nerve.

After arterial exposure is completed, other surgical tactics depend on the type of CC, according to W. Shamblin [3].

Type I: the tumor can be removed without damaging the vessel wall and tumor capsule.

Type II: the tumor is more tightly attached to the adventitia of the vessel and partially surrounds it, which makes it difficult to excise. However, removing a CC without damaging the arterial wall is possible.

Type III: the artery is cuffed by tumor tissue. This may require resection of the arterial fragment together with the tumor and further vessel reconstruction.

In order not to damage the artery, the tumor is dissected along the Gordon-Taylor "white line" [7]. Typically, the CC is supplied with blood from branches of the external carotid artery, which will be sutured, ligated, and crossed during tumor excision.

3) Arterial reconstruction

The arterial wall may be damaged during tumor excision. Therefore, effective arterial reconstruction is required by suturing the edges of the defect with 6-0 monofilament polypropylene sutures.

A total circular incision intentionally removes the section of the ICA completely surrounded by tumor tissue, and it is essential to ensure control of arterial bleeding in advance using vascular clips. After the CC and arterial fragment are removed "en bloc," the physiologic extent of the artery is restored by inserting a venous autograft by applying end-to-end vascular anastomoses with 6-0 monofilament polypropylene sutures.

Results: Between 2014 and 2021, 9 patients with CC were treated in our center. The clinical cases were evenly distributed by sex – 5 men and 4 women. The mean age was 42 years in men and 46 years in women. Table 1 provides clinical and demographic data of the study participants.

In 7 cases, the main complaint was a tumor-like neoplasm in the neck; 2 other patients had dysphagia and pain in the mass area. CABG was located unilaterally in all patients, including four left-sided and five right-sided cases. One patient had a Shamblin type I tumor, 5 had Shamblin type II tumors, and the remaining 3 had Shamblin type III tumors (Table 1).

Table 1 - Clinical and demographic data of the study participants

Indicators	N	Mean value (SD)
Gender		
Male	5	
Female	4	
Age		43.67 (13.4)
Number of bed-days		7.8 (3.2)
Chief complaint		
Formation of the neck	7	
Pain	1	
Dysphagia	1	
Type by Shamblin		
I	1	
II	5	
III	3	

In addition, two patients with Shamblin type I and type II tumors had a history of ACCD prior to PECC. Pathological tortuosity of the ICA was detected in 2 cases (Table 2).

Table 2 - Characteristics of the medical history of the study participants with carotid chemodectoma

Indicators	N
Pathological tortuosity	
Yes	2
No	7
ACCD	
Yes	2
No	7
PECC	
Not performed	1
Performed once	7
Performed twice	1

Note: ACCD – Acute cerebral circulation disorder; PECC – Preoperative embolization of the arteries feeding the carotid chemodectoma

8 of 9 patients underwent PECC. In 1 case, the patient underwent CC removal without preoperative embolization. As shown in Table 3, the tumor was partially removed in 2 cases and completely removed in 5 cases. One patient with Shamblin type II CC after PECC failed to appear for the second stage of treatment, and communication with him was lost. After ECC in 2 cases, arterial reconstruction was performed in patients with hemodynamically significant pathological tortuosity of the ICA to prevent ACCD.

Table 3 – Carotid chemodectoma resection degree in the study participants

The volume of resection of the mass	I	II	III	General
Not removed	0	1	0	1
Partially removed	1	0	1	2
Completely removed	0	4	2	6
Total	1	5	3	9

Intraoperative blood loss averaged 750 ml (50-1500 ml). Reinfusion was performed only in 5 cases. The average value was 243.3 ml. The average surgical time was 190 min. Tumor size was calculated according to the formula proposed by Arya et al. in 2008 [2]. The average size was 27.4 cm^3 (Table 4). In one case, a nerve was partially damaged during open surgery when the tumor was removed, which resulted in the patient's voice becoming hoarse. Subsequently, the patient underwent rehabilitation, as a result of which the phenomena of hoarseness and hoarseness were eliminated. The vocal function was fully restored. In the postoperative period, in all cases of CC, there were no complications and cases of patient death. Therefore, no paraganglioma malignization was registered in all cases.

Table 4 - Data from carotid chemodectoma excision surgery

Indicators	N	Mean value (SD)
Blood Loss		750 (502)
Reinfusion		243 (245)
Duration of operation (minutes)		191 (57)
Tumor size (cm^3)		27.4 (10.7)
Arterial reconstruction		
Performed	2	
Was not performed	7	
Nerve damage		
Yes	1	
No	8	

Discussion: CC is rare; according to a literature review, the incidence is between 1:30,000 and 100:100,000 [2]. We observe the same trend: in the last seven years, only nine patients with CC have been treated in NSOC. We analyzed morbidity, mortality, and other epidemiological data based on published worldwide data. Currently, there is no system for registering patients with CC in Kazakhstan; therefore, there are no epidemiological and other data on

the incidence of CC and the treatment results of this pathology.

It has been reported that CC is more common in women [3]; in the study group, the sex ratio was approximately equal (5 men and 4 women).

According to a literature review, CC occurs at all ages [4]. In this study, women were slightly younger compared to men.

Typically, CC is a unilateral tumor in 90% of cases; bilateral lesions are more common in the presence of CC in family members [5]. All patients observed had unilateral CC lesions and no CC cases in family members.

As in most published studies, all cases of UC presented in this study were benign.

CC is a slow-growing tumor, and usually, the main complaint of patients is swelling of the neck [5, 8]. CC usually grows without causing specific symptoms, so patients mostly had large type II and III tumors (Shamblin). Dysphagia, cough, and other clinical signs may occur due to compression of the vagus and sympathetic nerves [2]. However, it was impossible to determine the disease's exact period due to the lack of relevant information in the medical history. On physical examination, a tumor-like mass in the neck was noted to be mobile in the horizontal plane but fixed when trying to move vertically (Fontaine's symptom) [9]. Further, an ultrasound scan of the mass and CTA were performed to establish the tumor vascular structure.

In suspected CC, puncture and intraoperative biopsy of the tumor mass can lead to profuse bleeding. One patient had a history of attempted surgical resection of the mass. Intraoperatively, the tumor was found to encompass the ICA, after which the decision was made to suspend surgical treatment and perform a biopsy. Subsequently, on the second day after the surgery, ischemic ACCD occurred. After a course of rehabilitation, the patient underwent partial resection of the tumor in our center.

Surgical tactics remain an effective treatment for patients with CC instead of non-CC [5, 6]. Surgical treatment of non-CC is often associated with such complications as cranial palsy. Conservative treatment in the form of radiation therapy and active monitoring is recommended for this group of HNP. Therefore, an effective differential diagnosis between CC and non-CC is necessary to avoid complications and ensure adequate tumor growth control [5, 6].

A feature of CC is the presence of a rich vascular network, which makes surgical excision difficult due to the high risk of intraoperative bleeding. In our center, two-stage surgical treatment and PECC are performed before HNP. Some authors point out the insignificant effect of PECC on the volume of intraoperative blood loss and operation time [2]. In addition, we found that PECC reduces the risk of bleeding and surgery time. Surgical treatment in type I tumors (Shamblin) does not involve high intraoperative risks, such as damage to the CNs and great vessels with massive blood loss.

For the same reason, the disease is asymptomatic, and patients with CC seek care mostly with type II and III (Shamblin) when tumor removal becomes technically tricky and dangerous. ECC in the early stages of tumor growth prevents possible complications. ACCD is considered to be the most dangerous complication. However, among our clinical cases, we observed ACCD only before PECC. In one case, voice hoarseness was developed due to damage to the recurrent laryngeal nerve. Since the latter was enclosed in the tumor tissue, removing the cervical mass without nerve damage was not possible.

Conclusion: The status of the incidence of CC in Kazakhstan has not yet been studied, and a multicenter study should be initiated. Early diagnosis of CC with confirmation on USDS and CTA can reduce intraoperative risk from radical removal of the neoplasm. In our study, PECC allowed performing ECC without hemodynamically significant blood loss.

References:

1. Tulemissov A.K. Tactics of surgical treatment of patients with carotid chemodectomas // Oncology and Radiology of Kazakhstan. – 2019. – No. S. – P. 46. [Tulemissov A. K. Taktika hirurgicheskogo lechenija pacientov s karotidnymi hemodektomami // Onkologija i radiologija Kazahstana. – 2019. – №S. – S. 46 (in Russ.)]. https://www.elibrary.ru/download/elibrary_42631946_97382180.pdf ;

2. Darouassi Y., Alaoui M., Touati M.M., Maghraoui O.A., En-Nouali A., Bouaity B., Ammar H. Carotid body tumors: a case series and review of the literature // Annals Vasc. Surg. – 2017. – Vol. 43. – P. 265-271. https://doi.org/10.1016/j.avsg.2017.03.167 ;

3. Shamblin W.R., ReMine W.H., Sheps S.G., Harrison Jr.E.G. Carotid body tumor (chemodectoma): clinicopathologic analysis of ninety cases // Am. J. Surg. – 1971. – Vol. 122(6). – P. 732-739. https://doi.org/10.1016/0002-9610(71)90436-3;

4. Luna-Ortiz K., Rascon-Ortiz M., Villavicencio-Valencia V., Herrera-Gomez A. Does Shamblin's classification predict postoperative morbidity in carotid body tumors? A proposal to modify Shamblin's classification // Eur. Arch. Otorhinolaryngol. – 2006. – Vol. 263(2). – P. 171-175. Erratum: 14.09.2006. https://doi.org/10.1007/s00405-005-0968-4 ;

5. Abu-Ghanem S., Yehuda M., Carmel N. N., Abergel A., Fliss D. M. Impact of preoperative embolization on carotid body tumor surgery outcomes: a meta-analysis and review of the literature // Head Neck. – 2016. – Vol. 38(S1). – P. E2386-E2394. https://doi.org/10.1002/hed.24381 ;

6. Ikeda A., Shiga K., Katagiri K., Saito D., Miyaguchi J., Oikawa S.I., Tsuchida K., Asakage T., Ozawa H., Nibu K.I., Ohtsuki N., Fujimoto Y., Kaneko K.I. Multi-institutional survey of carotid body tumors in Japan // Oncol, Let. – 2018. – Vol. 15(4). – P. 5318-5324. https://doi.org/10.3892/ol.2018.7925;

7. Spinelli F., Massara M., La Spada M., Stilo F., Barillà D., & De Caridi G. A simple technique to achieve bloodless excision of carotid body tumors //Journal of Vascular Surgery. – 2014. – Vol. 59. – №. 5. – P. 1462-1464. https://doi.org/10.1016/j.jvs.2013.10.075;

8. Sajid M.S., Hamilton G., Baker D.M. A multicenter review of carotid body tumor management // ESVS. – 2007. – Vol. 34(2). – P. 127-130. https://doi.org/10.1016/j.ejvs.2007.01.015;

9. Kaygusuz I., Karlidag T., Keles E., Yalcin S., Yüksel K. Carotid body tumor: clinical features // J. Craniofac. Surg. – 2015. – Vol. 26(7). – P. e586-e589. https://doi.org/10.1097/SCS.0000000000002003.

ҰЛТТЫҚ ОНКОЛОГИЯЛЫҚ ҒЫЛЫМИ ОРТАЛЫҚТА КАРОТИДТІ ХЕМОДЕКТОМАНЫ ХИРУРГИЯЛЫҚ ЕМДЕУДІҢ КЕШЕНДІ ТӘСІЛІН ТАЛДАУ (НҰР-СҰЛТАН, ҚАЗАҚСТАН)

А.Қ. Тілемісов[1]

[1]«Ұлттық Ғылыми Онкологиялық Орталық» ЖШС, Нұр-Сұлтан, Қазақстан Республикасы

ТҰЖЫРЫМ

Өзектілігі: *Каротидті химодектомалар (КХ) барлық бас және мойын ісіктерінің арасында 0,01% жағдайда кездеседі. КХ қатерлі түрі 5-15% жағдайда байқалады. Каротид артерияларына тығыз бекітілуіне және ісіктің кең өсуіне байланысты операция кезінде негізгі қан тамырлары мен ми жүйкелері зақымдану қаупі жоғары, бұл өмірге қауіпті қан кетудің тез дамуына келтіруі мүмкін. Қазіргі кезеңде КХ радикалды алып тастау кезінде қан жоғалтуды азайту үшін КХ тамақтандыратын артерияларды операция алдындағы эмболизациялау (КХОАЭ) әдісі қолданылады.*

Мақсаты: *КХОАЭ арқылы КХ бар пациенттердің операция алдындағы дайындығының нәтижелерін бағалау; Қазақстан Республикасында осы аурудың ағымдағы мәртебесін анықтау үшін КХ-мен сырқаттанушылыққа мультицентрлік зерттеу жүргізу қажеттілігін негіздеу.*

Әдістері: *Барлық пациенттерде анамнез жиналды, аспаптық диагностикалық зерттеулер (ультрадыбыстық зерттеу (УДЗ), компьютерлік томографиялық ангиография (КТА)) жүргізілді. Luna-Ortiz et al. (2006) модификацияланған Shamblin (1971) бойынша КХ классификациясы қолданылды. (2006). КХ-ны радикалды жою алдында дайындық үшін ПЭКХ қолданылды. КХ радикалды алып тастау тактикасы Shamblin классификациясы бойынша КХ түріне байланысты таңдалды.*

Нәтижелері: *9 пациенттің 7 пациентінде негізгі шағым мойынның ісігіне, қалғандары ауырсыну мен дисфагияға қатысты. 4 пациентте КХ сол жақта, 5 пациентте – оң жақта орналасқан. 1 пациентте КХ I түрі Shamblin, 5 пациентте II түрі Shamblin, 3 пациентте III түрі Shamblin болды. 8 жағдайда КХОАЭ жүргізілді, 1 пациентке КХОАЭ-сіз радикалды операция жасалды. 8 жағдайда КХ оперативті алып тастуы жүргізілді, 1 науқас емдеудің екінші кезеңіне келмеді. 2 жағдайда артериялық қайта құру жүргізілді. Ісіктің орташа мөлшері – 27,4 см^3. КХ радикалды алып тастау кезінде айтарлықтай қан кетпеді, бұл эмболиялық агенттің болуымен байланысты. Орташа қан жоғалту – 750 мл, реинфузия – 243,3 мл құрады.*

Қорытынды: *Қазақстанда КХ ауруының жағдайы әлі зерттелген жоқ, көп орталықты зерттеуді бастау қажет. УДЗ және КТА негізінде ерте диагностикалау пациентті уақтылы және тиімді хирургиялық емдеумен қамтамасыз етуге мүмкіндік береді. КХОАЭ ісік резекциясын орындау үшін қолайлы жағдайларды қамтамасыз етті.*

Түйінді сөздер: *каротидті дененің ісігі, хемодектома, тамырлы неоплазма, каротидті бассейн, каротидті артериялардың реконструкциясы, эндоваскулярлық эмболизация.*

АНАЛИЗ КОМПЛЕКСНОГО ПОДХОДА К ХИРУРГИЧЕ-СКОМУ ЛЕЧЕНИЮ КАРОТИДНОЙ ХЕМОДЕКТОМЫ В УСЛОВИЯХ НАЦИОНАЛЬНОГО НАУЧНОГО ОНКОЛОГИЧЕСКОГО ЦЕНТРА (г. НУР-СУЛТАН, КАЗАХСТАН)

А.К. Тулемисов[1]

[1]ТОО «Национальный Онкологический Центр», Нур-Султан, Республика Казахстан

АННОТАЦИЯ

Актуальность: *Каротидные хемодектомы (КХ) среди всех онкологических заболеваний головы и шеи встречаются в 0,01% случаев. Злокачественная форма КХ наблюдается в 5-15% случаев. Плотное прикрепление к сонным артериям и экспансивный рост опухоли создают высокий риск повреждения магистральных артерий и черепно-мозговых нервов во время операции, которое может привести к развитию жизнеугрожающего кровотечения. На современном этапе для минимизации кровопотери при радикальном иссечении КХ (ИКХ) применяется метод предоперационной эмболизации артерий, питающих КХ (ПЭКХ).*

Цель исследования *– оценка результатов предоперационной подготовки пациентов с КХ посредством эмболизации артерий, питающих новообразование; обоснование необходимости проведения мультицентрового исследования заболеваемости КХ для определения текущего статуса заболевания в РК.*

Методы: *Сбор анамнеза, проведение инструментальных диагностических исследований (УЗИ, КТА). Использована классификация КХ по Shamblin (1971), модифицированная Luna-Ortiz с соавт. (2006). Для подготовки перед ИКХ применялась ПЭКХ. Тактика ИКХ подбиралась в зависимости от типа КХ по классификации по Shamblin.*

Результаты: *Из 9 пациентов с КХ, у 7 пациентов основная жалоба – на опухолевидное образование шеи, у остальных – боль и дисфагия. У 4 пациентов КХ располагалась слева, у 5 – справа. У 1 пациента КХ Shamblin тип I, у 5 – Shamblin тип II, у 3 – Shamblin тип III. В 8 случаях проводилась ПЭКХ, 1 пациент был оперирован без ПЭКХ. В 8 случаях проводилась ИКХ, 1 пациент на второй этап лечения не явился. В 2 случаях была проведена артериальная реконструкция. Средний размер опухоли – 27,4 см^3. ИКХ было без значительного кровотечения, что связано с присутствием эмболического агента. В среднем кровопотеря составила 750 мл, реинфузия – 243,3 мл.*

Заключение: *Статус заболеваемости КХ в Казахстане пока не изучен, необходимо инициировать многоцентровое исследование. Ранняя диагностика на основе УЗИ и КТА позволяет обеспечить пациента своевременным и эффективным хирургическим лечением. ПЭКХ обеспечивает благоприятные условия для выполнения резекции опухоли без гемодинамически значимой кровопотери.*

Ключевые слова: *каротидная хемодектома, опухоль каротидного тельца, параганглиома, эмболизация, каротидный бассейн, артерии.*

Transparency of the study: *The author takes full responsibility for the content of this manuscript.*
Conflict of interest: *The author declares no conflict of interest.*
Financing: *The author declares no financing of the study.*
Author's input: *contribution to the study concept – A.K. Tulemissov; study design – A.K. Tulemissov; execution of the study – A.K. Tulemissov; interpretation of the study – A.K. Tulemissov; preparation of the manuscript – A.K. Tulemissov.*
Authors' data:
Tulemissov A.K. (corresponding author) – 4 years resident, Center for Vascular Surgery National Research Oncology Center LLP, Kerey-Zhanibek khandar str. 3, Nur-Sultan 020000, the Republic of Kazakhstan, tel. +77775457000, e-mail: abaytulemissov@gmail.com, ID ORCID: https://orcid.org/0000-0001-7253-0033.