UDC: 616.61.006-089(87):615.849
DOI: 10.52532/2663-4864-2021-3-61-15-20

K.T. SHAKEYEV[1,2], N.A.KABILDINA[2], A.M. ZHUMAKAEV[1], A.S. TOKSAMBAEVA[1], S.V. SURMIN[1], A. ELUBAYULY[1], Sh.S. NURALY[2], A.A. KOKIMOV[2]

[1]Multidisciplinary hospital No.3, Karaganda, the Republic of Kazakhstan;
[2]JSC «Karaganda Medical University,» Karaganda, the Republic of Kazakhstan

The capacity of computed tomography in preoperative determination of surgery volume in kidney tumors

Relevance: *Computed tomography allows detecting small tumors. However, surgical tactics cannot always be determined in advance.*

The purpose of the research *was to assess the capacity of computed tomography in the preoperative determination of surgery volume in kidney tumors.*

Results: *548 patients were treated for kidney neoplasms. They were divided into three groups by computed tomography based on the R.E.N.A.L. scale: with a high risk of complications – 265 patients (48.4%), medium risk – 107 (19.5%), and low risk – 176 (32.1%). All operations were performed in the planned volume depending on the identified risk group for complications and resectability of kidney neoplasms; no changes to the plan of surgical interventions were made. The preoperative assessment of the kidney angioarchitectonics and the tumor relation to the pyelocaliceal system and the organ parenchyma helped determine the surgery volume and the possibility for organ-reserving interventions in 283 patients and radical nephrectomy in 265 patients.*

Conclusion: *Such a highly informative method as computed tomography made allows early detection of small-sized kidney tumors to provide an opportunity for organ-preserving surgery and improved treatment outcome.*

Keywords: *Kidney cancer, computed tomography, nephrectomy, kidney resection.*

Introduction:

Renal neoplasms rank 8th (3.81%) in cancer incidence in the Republic of Kazakhstan. The lethality from kidney cancer is 2.6% [1].

In the US, 30 thousand new cases and 12,000 deaths from kidney cancer are annually registered. There is an annual increase in the disease: from 1.5 to 5.9% in the US; in Russia, the growth rate was up to 3.5%. In 2016, 62,700 people in the USA were diagnosed with malignant kidney tumors, and 14,240 died from this disease. Renal cell carcinomas account for nearly 90% of kidney tumors [2].

According to the statistics, kidney cancer accounts for 4-5% of cancer cases in men and less than 3% of cancer cases in women [3]. According to the observations of the Russian oncologists, more than 20,000 new cases of renal malignancies were diagnosed in three years (2015–2018), with no decreasing tendency in the incidence of this disease. Kidney cancer is the most common among all kidney malignancies. Stage I was diagnosed in 47.9% of cases, stage IV – in 19.1%. This fact shows a high informative significance of radio diagnostic methods. High mortality (15.2%) from kidney cancer is mainly due to an advanced process [4, 5].

Nephrobiopsy is a reliable diagnostic method but is not a routine in renal tumors and is not performed in all institutions. In most cases, malignancy is confirmed after renal resection or nephrectomy [3].

Renal biopsy is not a safe technique and is more common during differential diagnostics or choice of therapy in metastatic lesions (6). However, L. Marconi et al. report relatively high diagnostic accuracy of renal biopsy in renal neoplasms at 90.1% despite the biopsy-associated difficulties and possible complications, including implantation metastases [7].

Kusainova B.T. proposes to use cytology to verify benign and malignant renal neoplasms and determine the most common histological variants. This method of morphological verification is of high significance and enables intraoperative determination of further tactics and scope of surgery [8].

It is crucial to preserve the quality of life of patients after renal surgery for neoplasms. On the one hand, the desire to perform organ-preserving surgery is justified; on the other hand, the main principle of radicality sometimes brings the oncourology doctor to a dead end. Radiation examination methods can assist in choosing between surgery with a high degree of radicality and the organ-preserving option in advance, before surgery.

In Russia, the number of organ-preserving operations with malignant renal neoplasms has increased by 15.5% in recent decades [9, 10].

K.T. Shakeyev – 0000-0002-7802-1464, e-mail: *shakeev@qmu.kz*

Preservation of the adrenal cortex is not always indicated in radical nephrectomy. Only tumor localization in the superior pole with adrenal cortex invasion is an indication for adrenalectomy.

Sometimes, the tumor size requires radical nephrectomy with lymph node dissection, and the technical possibilities for organ-preserving interventions are not always considered.

It is relatively easier to remove the kidney than resect it, even with the temporarily cut-off blood flow. As a result, radical nephrectomies are more common, and the kidney incision line is controlled on the gross specimen. The incidence of unnecessary nephrectomies was still relatively high in 2015, though the share of organ-preserving operations has reached 18.9% [11].

Russian researchers have noted that nephrectomies are most common in malignant renal neoplasms, and the desire of oncourologists to perform radical operations subordinates organ-preserving surgery.

In the past, the possibility for organ-preserving surgery in renal tumors was mainly determined by vessel size and relation. Today, the R.E.N.A.L. nephrometric scale is used in clinical practice when choosing organ-preserving surgery, predicting and preventing complications (Table 1).

Table 1 – R.E.N.A.L. scale [12]

Parameters	1 point	2 points	3 points
R – Radius, cm[a]	≤4	>4, but <7	≥7
E – Exophytic/endophytic[b]	≥50 % exophytic	<50 % exophytic	Predominantly endophytic
N – Nearness, mm[c]	≥7	>4, but <7	≤4
A – Anterior/posterior[d]	front	back	another
L – Location[e]	Figure 1		

[a] The largest diameter.
[b] Nature of growth.
[c] Proximity to the collecting system or sinus.
[d] Location of tumor (does not affect the score).
[e] Position concerning the pole lines.

Calculations based on the scale scores are as follows: a score of 10 to 12 indicates a high risk of complications, 7 to 9 – a moderate risk, and 4 to 6 – a low risk.

A differentiated approach to choosing the scope of surgery using the R.E.N.A.L. scale reduces the number of unnecessary nephrectomies. It fine-tunes organ-preserving surgery, improving oncological and functional outcomes in patients with malignant renal neoplasms [12].

The presented schematic pictures can be used to plan the incision line and the feasibility of organ-preserving surgery in general (Figure 1) [12]. It clearly shows the location of the mass and the renal pole position without considering the vascular masses. Unnecessary nephrectomies in renal neoplasms are shown when organ-preserving surgery could have been performed. Alexeeva G.N. et al. (2018) proposed measures that fine-tune the organ-preserving surgery, improve oncological and functional outcomes of localized kidney cancer treatment. This scheme shall be widely used in clinical oncourology.

The need for radical surgery and the surgeon's desire to preserve the kidney some-times confound this dilemma. Knowing the exact position of the tumor and the vessels and other anatomical structures of the kidney allows determining the scope of surgery well in advance.

In renal malignancy surgery, nephrectomy and resection of the kidney are the main methods of renal tumor treatment. Radiation methods can detect small masses but cannot always determine the surgical tactics in advance. Preserving a kidney with cen-tral renal masses is almost always challenging, given that surgery is the only choice. There is literature evidence of unnecessary nephrectomy at the early stages of the dis-ease.

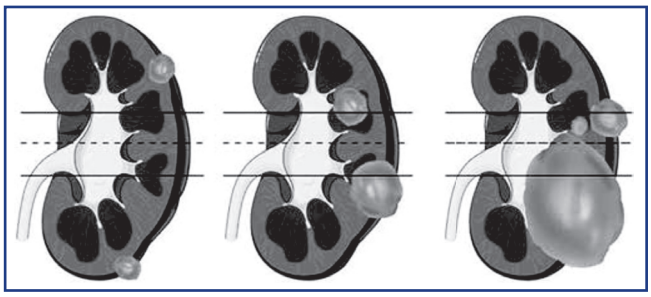

a – the tumor is located in one of the poles (1 point);
b – the tumor crosses the pole line (2 points);
c – more than 50% of the tumor is located behind the pole line, the tumor crosses the midline of the kidney, or the tumor is located between the pole lines (3 points);
h – if the tumor is adjacent to an artery and/or vein of the renal sinus (hilar tumor), add suffix "h."

Figure 1 – Kidney formation position related to the pole [12]

The rationale of organ-preserving surgery was proven in 25-years multicentre studies. Thus, among 3,457 patients with stage I and II renal neoplasms, 40% under-went nephrectomy vs. 60% of kidney resections. There was a reliable correlation be-tween glomerular filtration rate and lethality from malignant neoplasms. Antonelli et al. supported the kidney resection based

on the renal function effect on cancer treatment results. At that, each unit of glomerular filtration rate indicated the possibility of kidney preservation [13].

Tumor size matters the same as the tumor localization and its proximity to vas-cular structures. In the known literature, authors have demonstrated the feasibility and advisability of organ-preserving surgery for tumors over 6-7 cm. Thus, the median survival of patients after renal resection was higher than after nephrectomy. It should be noted that organ-preserving operations are associated with more complications due to possible bleeding from the renal parenchyma and related purulent-infectious pro-cesses. Specific technical difficulties might occur after renal resection due to possible bleeding from the renal parenchyma vessels even after temporary clamping of the renal artery. High-energy equipment does not always ensure definitive hemostasis. Only a combined use of high power, a Tachacomb plate, and stitching deliver definitive he-mostasis. However, despite frequent complications, renal resection provides a higher survival rate and better functional results than nephrectomy [14].

Surgical treatment is the primary choice in renal neoplasia. Advanced determina-tion of the scope of surgery is crucial for a favorable outcome. Such diagnostic tech-niques as morphology, renal ultrasound, and radioisotope renography have some in-formative value. However, only computerized tomography provides sufficient infor-mation about the state of the kidney and its vessels, the localization of the mass, and the relation to the pelvic ureteric segment and the surrounding organs.

The experience in treating patients with malignant renal neoplasms calls for a broader introduction of organ-preserving operations. The criteria for preferring resec-tion over nephrectomy as a radical surgical treatment in renal cancer are known.

The purpose of the research was to assess the capacity of computed tomography in the preoperative determination of surgery volume in kidney tumors.

Materials and methods:

A total of 548 surgeries (311 (56.8%) in men and 237 (43.2%) in women) for kidney neoplasms were performed at the Multidisciplinary hospital No.3 of Karaganda in 2016-2020.

We divided the patients into three groups depending on the tumor localization and size. In Group 1 (n=265, 48.4%), the patients had intrarenal tumors involving renal collar and pelvic segment. Intrarenal tumors also presented complications by portal vein thrombosis in 11 patients and tumor invasion into the adjacent organs in 13 patients.

In Group 2 (n=107, 19.5%), the tumors were located near the upper pole of the kidney and were up to 6-7 cm in size.

In Group 3 (n=176, 32.1%), the patients had neoplasms of the lower pole (n=85, 48.3%) and the kidney rib (n=91, 51.7%), with the tumor size of 2-5 cm.

All patients underwent computed tomography to determine the kidney angioarchitecture, the exact localization of the tumor, its relation to the calyx-pelvic system and blood vessels, and possible options for invasion into adjacent organs. No preoperative renal biopsy was performed in our study.

The R.E.N.A.L. scale was used to determine the feasibility of organ-preserving surgery and the development of complications. All the patients were attributed to three groups by the risk of complications according to their R.E.N.A.L. scores.

In Group 1, most tumors were localized at the center, near the vessels, or close to the kidney arteries and veins and could not be bypassed. Some patients had thrombosis of the portal and renal veins and tumor invasion into adjacent organs. Together, it was an indication for radical nephrectomy. The average size of intrarenal tumors was 7 to 12 cm. Tumor localization in the lower pole of the kidney with involvement of the calyx-lobar segment was another indication for nephrectomy (Figure 2). The below picture clearly shows the tumor location with the infiltration of the pelvic cavity, making it impossible to maintain the kidney (a series of abdominal CT scans with contrast showed an additional rounded mass measuring over 7 cm, with heterogeneous density, in the lower pole of the right kidney). This tumor was apprised as a locally disseminated tumor.

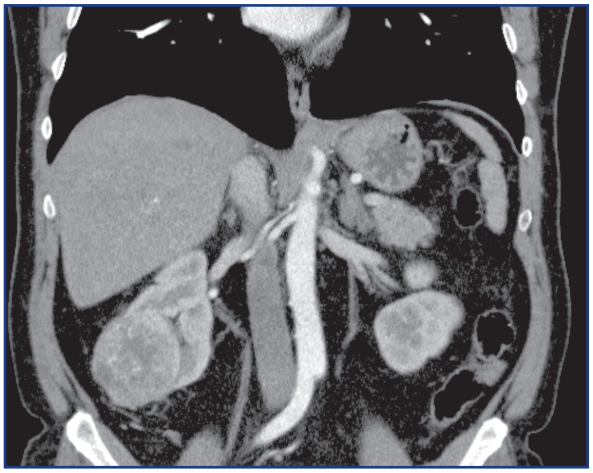

Figure 2 – Abdominal CT with the tumor in the lower pole of the right kidney, involving the calyx-pelvic segment.

In Group 2 of moderate risk, the tumors 4-5 cm in size were located in the upper pole, relatively distant from blood vessels. The R.E.N.A.L. scale for these tumors was 8 points, and they were assessed resectable. Organ-preserving surgery, with a mandatory temporary cessation of the renal blood flow, was planned (Figure 3).

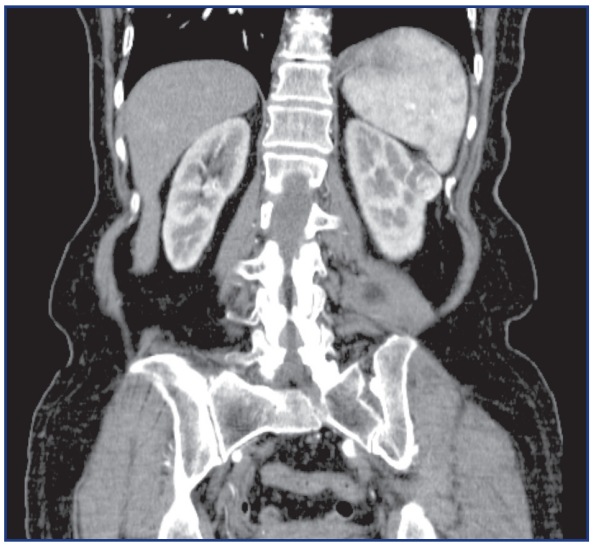

Figure 3 – Abdominal CT scan of a left kidney tumor.

In the low-risk Group 3, the renal neoplasms were up to 4 cm in size and located far from the vessels, so they were assessed resectable. The below picture shows a CT scan of a tumor along the rib of the left kidney with no connection to the portal and vessels or the pelvic system. (Contrast-enhanced CT scans of the abdomen in the frontal plane show an additional irregularly rounded, heterogeneous mass measuring up to 2.3 cm, intensely accumulating contrast, on the lateral contour of the left renal parenchyma, in the middle 1/3 of the left kidney. No involvement of the RCS is detected). This CT scan made it possible to plan the scope of surgery before the operation.

In this group, not all cases required renal vasoconstriction. Accordingly, the operation proceeded without technical difficulties, provided that high-energy equipment was used.

Results and Discussion:

In Group 1, all patients (n=265, 48.4%) with a high risk of complications and tumor nature according to the R.E.N.A.L. scale underwent radical nephrectomy. Most technical difficulties were registred in case the tumor invaded the neighboring organs: colon and mesocolon – in 7 patients, pancreas – 2, right lobe of the liver – 1. Colon resections with primary anastomoses were performed in case of colonic infiltration. No postoperative complications were registered, intestinal activity was restored. At caudal-pancreatic gland outgrowth in 2 patients, a corporocaudal resection was performed for radicality. Inferior vena cava thrombosis was observed in 9 patients, renal vein thrombosis – in 2 patients. Nephrectomy was performed with vena cava thrombectomy (Figure 4). Thrombectomies with the restoration of the defect in the vein were associated with some technical difficulties. The thrombus was 4-7 cm long. No postoperative thrombogenic complications were noted.

Figure 4 shows a right kidney with a large tumor and multiple satellite metastases in the parenchyma. A renal vein with a tumor embolus, most often in the vena cava, is visible. Histological examination of the tumor revealed a renal cell carcinoma.

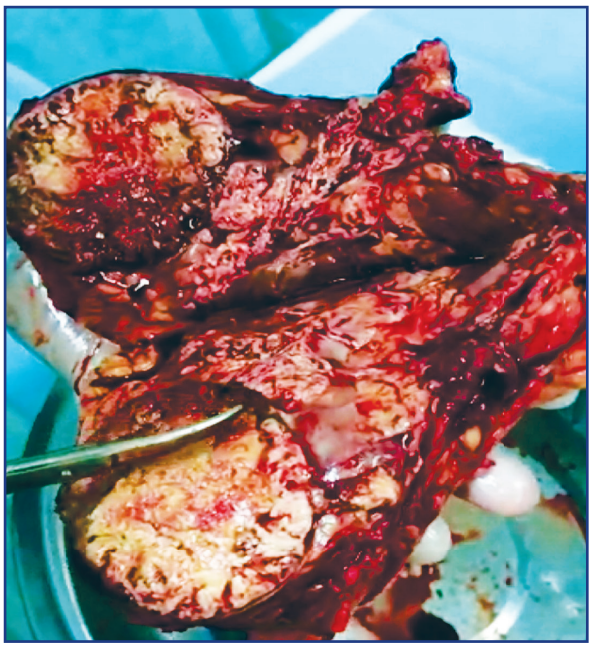

Figure 4 – Macropreparation: kidney with a tumor in the lower pole and a thrombus in the vena cava.

In 263 (48.0%) patients, organ-preserving surgery was performed. Anatomical landmarks made it possible to prevent damage to the large vessels and to predict possible atypical resection in advance. 203 (37.0%) patients underwent nephrectomy for large tumors with lesions of the calyx-pelvic system and invasion into the pararenal fat body; 39 of them underwent laparoscopic surgery.

In Group 2, 107 (19.5%) patients with a moderate risk of complications and a high possibility for organ-preserving interventions presented some intraoperative difficulties like bleeding after a segment resection and the renal blood flow opening. The event was resolved with technical difficulties using high-energy equipment – Tachacomb hemostatic plates.

In Group 3, 176 (32.1%) patients had good technical intraoperative conditions for organ-preserving surgery (Figure 5).

Figure 5 clearly shows a removed tumor with a line of healthy renal tissue, indicating the radical nature of the operation.

Probably, the small size of the tumor and its more superficial location enabled resection and kidney preservation in all patients in this group to undergo. Those 39 patients did not require the renal vessels' clamping.

Our study confirmed a high R.E.N.A.L. scale effectiveness for preoperative determination of further surgical tactics and performing organ-preserving opera-

tions with a high degree of substantiation. This scale can be recommended for wide use in clinical practice. The method allows not only to set indications for organ-preserving operations but also to justify the radical scope of surgery in locally disseminated processes and reduce the risk of subjective assessment of the scope of intervention.

Figure 5 – Resected kidney section with a tumor removed within healthy tissue

Conclusion:

The primary purpose was to assess the feasibility of using CT in presurgical diagnostics of renal neoplasms to determine the scope of surgery. Retrospective and prospective analyses of operations performed in patients with renal neoplasms revealed a correlation between the tumor nature by the R.E.N.A.L. scale and the type of surgery required. The analysis of 548 surgical interventions in patients with renal neoplasms revealed three groups depending on the risk of complications and tumor resectability according to the R.E.N.A.L. scale score.

Presurgical assessment of the kidney angioarchitecture and the tumor relation to the calyx-pelvic system and blood vessels allowed determining the scope of surgery and the possibility of preserving the kidney in advance.

The use of the R.E.N.A.L. scale to group patients in need of nephrectomy or organ-preserving surgery provided good treatment outcomes in patients with renal neoplasms.

Computed tomography has a high informative value in diagnosing kidney neoplasms and plays an essential role in determining the volume of surgical intervention. This method allows specifying indications for organ-preserving operations.

The article describes the use of the R.E.N.A.L. scale based on computed tomography data to determine the scope of surgery in kidney neoplasms. Only correctly performed calculations by this scale made it possible to determine the volume of surgery in all patients correctly. 283 patients with medium and low risk of complications and resectable tumors underwent organ-preserving surgery. The use of the R.E.N.A.L. scale provides a real opportunity to objectify the indications for nephrectomy and organ-preserving operations in patients with renal neoplasms.

References:

1. Pokazateli onkologicheskoj sluzhby Respubliki Kazaxstan za 2019 g. (statisticheskie i analiticheskie materialy) / pod red. Kajdarovoj D.R. – Almaty: Kazaxskij Nauchno-Issledovatel'skij Institut Onkologii i Radiologii, 2020. – 225 s. [Indicators of the oncological service of the Republic of Kazakhstan for 2019 (statistical and analytical materials) / ed. D.R. Kaidarova. – Almaty: Kazakh Institute of Oncology and Radiology, 2020. – 225 p.] https://onco.kz/news/pokazateli-onkologicheskoj-sluzhby-respubliki-kazahstan-za-2018-god-statisticheskie-i-analiticheskie-materialy-2/ (in Russian);

2. Motzer R.J., Jonasch E., Agarwal N., Bhayani S., Bro W.P., Chang S.S., Choueiri T.K., Costello B.A., Derweesh I.H., Fishman M., Gallagher T.H., Gore J.L., Hancock S.L., Harrison M.R., Kim W., Kyriakopoulos C., LaGrange C., Lam E.T., Lau C., Michaelson M.D., Olencki T., Pierorazio P.M., Plimack E.R., Redman B.G., Shuch B., Somer B., Sonpavde G., Sosman J., Dwyer M., Kumar R. Kidney Cancer, Version 2.2017, NCCN Clinical Practice Guidelines in Oncology // J. Natl. Compr. Canc. Netw. – Vol. 15(6). – P.804-833. https://doi.org/10.6004/jnccn.2017.0100;

3. Siegel R.L., Miller K.D., Jemal A. Cancer statistics, 2018 // CA Cancer J. Clin. – 2018. – Vol. 68(1). – P. 7-30. https://doi.org/10.3322/caac.21442;

4. Zlokachestvennye novoobrazovaniya v Rossii v 2017 godu (zabolevaemost' i smertnost') / pod red. A.D. Kaprina, V.V. Starinskogo, G.V. Petrovoj. – M.: MNIOI im. P.A. Gercena – filial FGBU «NMIC radiologii» Minzdrava Rossii, 2018. – 250 s. [Malignant neoplasms in Russia in 2017 (morbidity and mortality) / eds. A.D. Kaprin, V.V. Starinsky, G.V. Petrova. – M.: MNIOI n.a. P.A. Herzen - branch of the Federal State Budgetary Institution "National Medical Research Center of Radiology" of the Ministry of Health of Russia, 2018. – 250 p.] https://glavonco.ru/upload/pages/cancer-register/statistika_zabol_2017.pdf (in Russian);

5. Sostoyanie onkologicheskoj pomoshhi naseleniyu Rossii v 2017 godu / pod red. A.D. Kaprina, V.V. Starinskogo, G.V. Petrovoj. – M.: MNIOI im. P.A. Gercena – filial FGBU «NMIC radiologii» Minzdrava Rossii, 2018. – 236 s. [The state of public cancer care in Russia in 2017 / eds. A.D. Kaprin, V.V. Starinsky, G.V. Petrova. – M.: MNIOI n.a. P.A. Herzen – branch of the Federal State Budgetary Institution "National Medical Research Center of Radiology" of the Ministry of Health of Russia, 2018. – 236 p.] https://oncology-association.ru/wp-content/uploads/2020/09/sostoyanie_2017.pdf (in Russian);

6. EAU Guidelines on Renal Cell Carcinoma. – 2018. – 70 p. https://uroweb.org/wp-content/uploads/EAU-RCC-Guidelines-2018-large-text.pdf;

7. Marconi L., Dabestani S., Lam T.B. et al. Systematic review and meta-analysis of diagnostic accuracy of percutaneous renal tumour biopsy // Eur. Urol. – 2016. – Vol. 69(4). – P. 660-673. https://doi.org/10.1016/j.eururo.2015.07.072;

8. Kusainova B.T. Vozmozhnosti morfocitologicheskoj verifikacii opuxolej pochek // Onkologiya i radiologiya Kazaxstana. – 2012. – №1. – S.27–28 [Kusainova B.T. Possibilities of morphocytological verification of kidney tumors // Oncology and Radiology of Kazakhstan. – 2012. – No. 1. – P. 27-28]. http://oncojournal.kz/wp-content/uploads/2012/2012.1.23_07.pdf (in Russian);

9. Apolixin O.I., I.V. Chernyshev, D.A. Pavlov i dr. Tendencii razvitiya e'ndovideoxirurgii lokalizovannogo raka pochki / Mat.

XIV kongressa ROU. – Saratov, 2014. – S. 247-248 [Apolikhin O.I., Chernyshev I.V., Pavlov D.A. et al. Trends in the development of endovideosurgery of localized kidney cancer / Mat. XIV Congress of the ROU. – Saratov, 2014. – P. 247-248] (in Russian);

10. Volkova M.I., Skvorcov I.Ya., Klimov A.V., Chernyaev V.A., Komarov M.I., Matveev V.B., Peters M.V. Vliyanie ob»ema xirurgicheskogo vmeshatel'stva na funkcional'nye rezul'taty i kardiospecificheskuyu vyzhivaemost' u bol'nyx klinicheski lokalizovannym rakom pochki // Onkourologiya. – 2014. – T.10(3). – S. 22-30 [Volkova M.I., Skvortsov I.Ya., Klimov A.V., Chernyaev V.A., Komarov M.I., Matveev V.B., Peters M.V. Influence of the volume of surgical intervention on functional results and cardiospecific survival in patients with clinically localized kidney cancer // Oncourology. – 2014. – T.10 (3). – P. 22-30]. https://cyberleninka.ru/article/n/vliyanie-obema-hirurgicheskogo-vmeshatelstva-na-funktsionalnye-rezultaty-i-kardiospetsificheskuyu-vyzhivaemost-u-bolnyh-klinicheski (in Russian);

11. Alekseeva G.N., Gurina L.I., Mazalov B.V., Filippov A.G., Volkov M.V. E'ffektivnost' i bezopasnost' organosoxranyayushhix operacij pri lokalizovannom rake pochki // Onkourologiya. – 2015. – T.11(1). – S. 20-25 [Alekseeva G.N., Gurina L.I., Mazalov B.V., Filippov A.G., Volkov M.V. Efficiency and safety of organ-preserving surgeries in localized kidney cancer // Oncourology. – 2015. – T.11(1). – P. 20-25]. https://oncourology.abvpress.ru/oncur/article/view/413 (in Russian);

12. Alekseeva G.N., Pisareva L.F., Gurina L.I. Volkov M.V., Krepkix I.V., Yudin M.V. Organosoxranyayushhie operacii pri rake pochki kak sposob uluchsheniya rezul'tatov lecheniya. Obzor klinicheskix sluchaev // Tihookeanskij medicinskij žurnal. – 2018. – №1. – S. 64-66 [Alekseeva G.N., Pisareva L.F., Gurina L.I. Volkov M.V., Krepkikh I.V., Yudin M.V. Organ-preserving surgery for kidney cancer as a way to improve treatment results. Review of clinical cases // Pacific Medical Journal – 2018. – №1. – P. 64-66]. https://www.tmj-vgmu.ru/jour/article/view/212/212 (in Russian);

13. Antonelli A., Minervini A., Sandri M., Bertini R., Bertolo R., Carini M., Furlan M., Larcher A., Mantica G., Mari A., Montorsi F., Palumbo C., Porpiglia F., Romagnani P., Simeone C., Terrone C., Capitanio U. Below safety limits, every unit of glomerular filtration rate counts: Assessing the relationship between renal function and cancer-specific mortality in renal cell carcinoma // Eur. Urol. – 2018. – Vol. 74(5). – P. 661-667. https://doi.org/10.1016/j.eururo.2018.07.029;

14. Janssen M.W.W., Linxweiler J., Terwey S., Rugge S., Ohlmann C.-H., Becker F., Thomas Ch., Neisius A., Thuroff J.W., Siemer S., Stockle M., Roos F.C. Survival outcomes in patients with large (≥7cm) clear cell renal cell carcinomas treated with nephron-sparing surgery versus radical nephrectomy: Results of a multicenter cohort with long-term follow-up // PLoS One. – 2018. – Vol. 13(5). – e0196427. https://doi.org/10.1371/journal.pone.0196427.

ТҰЖЫРЫМ

К.Т. Шакеев[1,2], Н.А. Кабилдина[2], А.М. Жумакаев[1], А.С. Токсамбаева[1], С.В. Сурмин[1], А. Елубайұлы[1], Ш.С. Нұралы[2], А.А. Кокимов[2]

[1]Қарағанды қаласы №3 көпсалалы ауруханасы, Қарағанды, Қазақстан Республикасы;
[2]«Қарағанды медицина университеті», Қарағанды, Қазақстан Республикасы

Бүйрек ісіктері кезіндегі операция көлемін алдын ала анықтау үшін компьютерлік томографияның мүмкіндіктері

Өзектілігі: *компьютерлік томография көмегімен кішкентай мөлшердегі бүйректің ісіктерін анықтауға болады, бірақ емдеудің хирургиялық тактикасын әрдайым алдын-ала анықтау мүмкін емес.*

Мақсаты: *бүйрек ісіктері үшін хирургиялық араласу көлемін анықтау үшін компьютерлік томография арқылы операция алдындағы диагноздың мүмкіндіктерін бағалау.*

Нәтижелері: *бүйрек ісіктері бар 548 науқас емделді. Компьютерлік томографияны пайдалана отырып, R.E.N.A.L. шкласы негізінде үш топ бөлінді: бірінші топта асқынулардың даму қаупі жоғары– 265 науқас (48,4%), орташа қауіп деңгейі – 107 (19,5%) және төмен деңгейлі қауіп – 176 (32,1%). Операциялардың барлық жоспарланған көлемі асқынулардың және бүйрек ісіктерінің резектабельділігі қаупінің белгіленген топтарына сәйкес орындалды, бұл ретте операциялық араласулар жоспарында өзгерістер болған жоқ. Бүйрек ангиоархитектоникасын және тостағанша жүйесі мен мүше паренхимасына қатынасын операция алдындағы бағалау, операция көлемін және 283 науқаста мүше сақтайтын араласуды және 265 науқаста радикалды нефрэктомияны орындау мүмкіндігін анықтауға мүмкіндік берді.*

Қорытынды: *компьютерлік томография сияқты жоғары ақпараттық әдіс аурудың ерте кезеңдерінде шағын бүйрек ісіктерін анықтауға, ағзаны сақтау операциясын жасау және емдеу нәтижелерін жақсартуға мүмкіндік береді.*

Түйінді сөздер: *бүйрек қатерлі ісігі, компьютерлік томография, нефрэктомия, бүйрек резекциясы.*

АННОТАЦИЯ

К.Т. Шакеев[1,2], Н.А. Кабилдина[2], А.М. Жумакаев[1], А.С. Токсамбаева[1], С.В. Сурмин[1], А. Елубайұлы[1], Ш.С. Нұралы[2], А.А. Кокимов[2]

[1]КГП на ПХВ Многопрофильная больница №3, г. Караганда, Республика Казахстан;
[2]НАО «Медицинский Университет Караганды», г. Караганда, Республика Казахстан

Возможности компьютерной томографии для предоперационного определения объема операции при новообразованиях почек

Актуальность: *При помощи компьютерной томографии удается выявить новообразования почек небольших размеров, однако хирургическая тактика лечения не всегда может быть заблаговременно определена.*

Цель: *оценить возможности предоперационной диагностики посредством компьютерной томографии для определения объема оперативного вмешательства при новообразованиях почек.*

Результаты: *Было пролечено 548 больных с новообразованиями почек. Нами выделены три группы на основе шкалы R.E.N.A.L. с использованием компьютерной томографии: с высоким уровнем риска развития осложнений – 265 больных (48,4%), средним уровнем риска – 107 (19,5%) и низким уровнем риска – 176 (32,1%). Все запланированные объемы операций были выполнены согласно выделенным группам риска развития осложнений и резектабельности новообразований почки, при этом изменений в плане оперативных вмешательств не было. Предоперационная оценка ангиоархитектоники почки и отношения опухоли к чашечно-лоханочной системе и паренхиме органа позволила определить объем операции и возможность выполнения органосохраняющих вмешательств у 283 больных и радикальную нефрэктомию – у 265.*

Заключение: *Такой высокоинформативный метод, как компьютерная томография, позволяет выявить новообразования почек небольших размеров на ранних стадиях заболевания, когда имеется возможность выполнить органосохраняющую операцию и, соответственно, улучшить результаты лечения.*

Ключевые слова: *рак почек, компьютерная томография, нефрэктомия, резекция почек.*